Bone and Arthrosurgery Science

Editors-in-Chief

Kenneth M.C. Cheung

The University of Hong Kong, Hong Kong SAR, China

Biao Wang

Honghui Hospital Affiliated to Xi'an Jiaotong University, China

BIO-BYWORD SCIENTIFIC PUBLISHING PTY LTD
(619 649 400)
Level 10
50 Clarence Street
SYDNEY NSW 2000
Copyright © 2026. Bio-Byword Scientific Publishing Pty Ltd.
Complimentary Copy

Bone and Arthrosurgery Science

Focus and Scope

Bone and Arthrosurgery Science is a peer-reviewed articles across a wide spectrum of clinical treatise, basic research, review, frontier of orthopedics, case analysis and comment. This journal is aimed at professionals at all levels engaged in the basic and clinical work of orthopedics. Each issue is guest-edited by an acknowledged expert and focuses on a single topic or controversy.

It mainly reports new viewpoints, new achievements and new technologies in basic and clinical research of bone and joint surgery. The covered topics include, but are not limited to: sports medicine and arthroscopy, prosthetic design, biomechanics, biomaterials, metallurgy, biologic response to arthroplasty materials *in vivo* and *in vitro*.

About Publisher

Bio-Byword Scientific Publishing is a fast-growing, peer-reviewed and open access journal publisher, which is located in Sydney, Australia. As a dependable and credible corporation, it promotes and serves a broad range of subject areas for the benefit of humanity. By informing and educating a global community of scholars, practitioners, researchers and students, it endeavors to be the world's leading independent academic and professional publisher. To realize it, it keeps creative and innovative to meet the range of the authors' needs and publish the best of their work.

By cooperating with University of Sydney, University of New South Wales and other world-famous universities, Bio-Byword Scientific Publishing has established a huge publishing system based on hundreds of academic programs, and with a variety of journals in the subjects of medicine, construction, education and electronics.

Publisher Headquarter

BIO-BYWORD SCIENTIFIC PUBLISHING PTY LTD
Level 10
50 Clarence Street
Sydney NSW 2000
Website: www.bbwpublisher.com
Email: info@bbwpublisher.com

2026, Volume 4, Issue 5

Table of Contents

1 **Observation on the Therapeutic Effect of Acupuncture Combined with Microwave Therapy for Wrist Joint Training Injury Based on the Theory of "Tendons, Bones, and Muscles"**
Yonglong Zhang, Xiaofang Su

8 **Observation of the Improvement Effect of Unilateral Biportal Endoscopy on Neurogenic Symptoms in Lumbar Spinal Stenosis**
Han Zhang, Tong Wang, Hongyu Zhu, Bo Wu, Weiqing Li

15 **Seeing the Sumeru in a Mustard Seed: Zhu Jiakai and the Pioneering Journey of Microsurgery in China**
Manying Xie, Zhifang Lu, Di Lu, Xiaoxin Feng

25 **Effects of Extracorporeal Shock Wave Therapy on Visual Analogue Scale Scores and Serum Osteocalcin in Patients with Old Thoracolumbar Compression Fractures**
Zhenyu Wang

33 **Exploratory Comparison of Three Extracorporeal Shock Wave Energy Settings and Two Transosseous Fixation Configurations in a Rabbit Rotator Cuff Repair Model: A Pilot Study**
Lin Teng, Yue Zhang, Dahai Liu, Keyuan Ding, Gang Zhong

45 **Research Progress on the Correlation between Pseudogout and Periprosthetic Infection after Knee Joint Replacement Surgery**
Yijian Jiang, Chengsong Zou, Jiahao Lu, Ke Zhou, Qili Li, Weihao Yu, Le Chen, Xihua Zhang, Hongchi Yi

Bone and Arthrosurgery Science, 2026, Volume 4, Issue 5
https://www.bbwpublisher.com/journal/BAS
Online ISSN: 2981-8222
Print ISSN: 3083-4856

Observation on the Therapeutic Effect of Acupuncture Combined with Microwave Therapy for Wrist Joint Training Injury Based on the Theory of "Tendons, Bones, and Muscles"

Yonglong Zhang, Xiaofang Su*

Department of Traditional Chinese Medicine and Integrated Traditional Chinese and Western Medicine, Affiliated Hospital of Non-commissioned Officer School of Army Medical University, Shijiazhuang 050000, Hebei, China

Author to whom correspondence should be addressed.

Copyright: © 2026 Author(s). This is an open-access article distributed under the terms of the Creative Commons Attribution License (CC BY 4.0), permitting distribution and reproduction in any medium, provided the original work is cited.

Abstract: *Objective:* To observe the clinical efficacy of acupuncture combined with microwave in the treatment of wrist joint training injury based on the theory of "muscle and bone," and to verify the scientificity and practicability of this scheme in the treatment of wrist joint injury. *Methods:* Sixty patients with wrist injury were randomly divided into a control group and a treatment group, 30 cases in each group. The control group was treated with microwave combined with local Ashi point acupuncture, and the treatment group was treated with Taixi, Taichong, Yanglingquan, and Dazhu on the basis of the intervention of the control group. Each intervention lasted for 20 minutes, once a day, for 1 week as a course of treatment, and 2 courses of continuous intervention. Ultrasound examination was used to evaluate the recovery of wrist soft tissue before and after treatment. VAS pain score, Cooney wrist function score, and clinical efficacy evaluation criteria were selected as observation indicators to compare the improvement of wrist injury symptoms between the two groups. *Results:* The VAS pain score, the Cooney wrist function score, and the TCM syndrome score of both groups showed significant improvement after intervention compared to before intervention, with statistically significant differences ($P < 0.05$), suggesting that both intervention schemes could effectively reduce the pain symptoms caused by wrist training injury and promote the recovery of wrist joint function. The results of inter-group comparison showed that acupuncture combined with microwave treatment based on the theory of "muscle and bone" was superior to conventional treatment in relieving pain, improving the overall function of the wrist joint, and increasing the total clinical effective rate, with a statistically significant difference ($P < 0.05$). It is suggested that acupuncture combined with microwave therapy, based on the theory of "muscle and bone," can produce a synergistic therapeutic effect, which is more beneficial in correcting muscular imbalance, bone and muscle injuries caused by strain, and achieving the overall repair of wrist joint function. *Conclusion:* Acupuncture combined with microwave under the guidance of muscle and bone theory is effective in the treatment of wrist joint injury, which is worthy of clinical application.

Keywords: Muscle and bone theory; Wrist joint injury; Acupuncture; Microwave therapy; Traditional Chinese medicine

Online publication: November 20, 2026

1. Introduction

The earliest origin of the "tendons, bones, and muscles" concept can be traced back to the discussions on bones, tendons, and muscles in the *Huangdi Neijing*. The *Lingshu · Jingmai* clearly describes their physiological functions: "bones are the framework, vessels carry nutrients, tendons provide strength, and muscles form walls." Here, bones serve as the structural support of the body, providing stability; tendons act as connecting ligaments that bind and constrain bones; and muscles function as protective barriers, offering cushioning and defense. This discussion laid the theoretical foundation for the core therapeutic approach of regulating the functions of the liver, spleen, and kidneys in treating musculoskeletal disorders. As stated in the *Suwen · Weilun*: "The main tendons bind bones and facilitate joint movement," further explaining that tendons maintain the structural integrity of bones and joints, ensuring joint stability and normal physiological function. The *Suwen · Maiyao Jingwei Lun* states: "Bones house marrow; without sufficient nourishment, one cannot stand long, and walking causes trembling—this indicates bone exhaustion." This highlights the pivotal role of bones as a supportive structure, emphasizing that bones depend on marrow for nourishment, and any bone injury may lead to limb tremors and joint instability. The *Anyin Jiyi Bingzheng Fanglun · Neiyin Yaotong Lun* records: "The spleen and stomach are internally related; when the spleen is stagnant, and the stomach is blocked, lower back pain often occurs." If the spleen fails to properly transform food essence, nutrients will not be adequately produced, leading to insufficient nourishment of joints and muscles. Wind, cold, and damp pathogens may then invade, causing bi syndrome (arthritis). Additionally, if fluid metabolism is impaired, phlegm-damp accumulates internally, obstructing blood circulation and disrupting the flow of qi, which may also result in bi syndrome. Based on ancient physicians' understanding of the "tendons, bones, and muscles–liver, spleen, kidney" theory, modern medicine has further clarified its clinical value in treating musculoskeletal diseases, confirming that orthopedic treatment should emphasize comprehensive intervention involving soft tissues such as surrounding muscles, ligaments, and articular discs [1,2].

Acupuncture therapy in traditional Chinese medicine has proven effective for treating wrist joint injuries. However, previous studies have mostly focused on the perspectives of "liver and kidney, tendons and bones," while research based on the theory that "the spleen governs the muscles of the limbs" remains relatively scarce. As stated in the *Suwen · Bilun*: "When bi syndrome affects the bone, there is heaviness; when it affects the pulse, blood stagnates and fails to flow; when it affects the tendon, flexion is impaired; when it affects the flesh, numbness occurs; when it affects the skin, coldness arises." This passage indicates that bone, tendon, and muscle can all influence the progression of bi syndrome resulting from joint injury. Acupuncture may regulate the functional coordination among tendons, bones, and muscles by stimulating acupoints corresponding to the liver, spleen, and kidneys, thereby helping maintain normal physiological joint function. The wrist joint is one of the most complex anatomical joints in the human body, and wrist injuries rank first among musculoskeletal trauma in the upper extremity due to various acute and chronic sports-related injuries. Current clinical interventions primarily include ice application, topical anti-inflammatory ointments, local injections, and physical therapy, with surgery required for severe cases. However, repeated local injections may lead to tissue degeneration, while prolonged immobilization can cause local muscle atrophy. This study aims to evaluate the clinical efficacy of acupuncture combined with microwave therapy for wrist joint injuries, thereby verifying the reliability and practicality of the "tendon-bone-muscle" theoretical approach in treating joint disorders.

2. Materials and methods

2.1. Basic information

2.1.1. Case source

Sixty patients with wrist joint injuries were selected from the Department of Traditional Chinese Medicine at our hospital between June 2024 and June 2026, and randomly divided into a treatment group and a control group, each consisting of 30 cases.

2.1.2. Diagnostic criteria

According to the diagnostic criteria for wrist sprain and contusion in "Criteria of Diagnosis and Therapeutic Effect of Diseases and Syndromes in Traditional Chinese Medicine": there should be a clear history of wrist twisting, pulling, or ground impact injury; symptoms include swelling, pain, tenderness in the wrist, and restricted wrist joint mobility; X-ray examination must rule out fractures of the carpal bones or joint dislocation. Additionally, soft tissue injuries of the wrist (such as ligament, tendon, or joint capsule damage) may be included, which can involve TFCC injury.

2.1.3. Inclusion criteria

Meets the diagnostic criteria for wrist sprain and contusion as defined in the "Criteria of Diagnosis and Therapeutic Effect of Diseases and Syndromes in Traditional Chinese Medicine"; age 18–60 years, both genders eligible; duration of illness: acute injury ≤3 weeks; subacute or chronic injury 3 weeks to 6 months; VAS pain score ≥3 points; willing to participate in the study, able to cooperate with treatment, follow-up visits, and long-term monitoring, and has signed an informed consent form.

2.1.4. Exclusion criteria

X-ray/CT confirmed wrist fractures, dislocations, or bone cracks; complete tendon rupture; open injuries; wrist tumors, tuberculosis, or purulent arthritis; inflammatory arthritides such as rheumatoid arthritis, gout, and psoriatic arthritis; prior surgical history of the affected wrist joint; complex regional pain syndrome; concomitant severe systemic diseases including cardiac, hepatic, renal, or coagulation disorders; psychiatric conditions preventing cooperation with assessment; pregnant or breastfeeding women; individuals who have received local corticosteroid injections or taken potent oral analgesics within the past week, which may interfere with efficacy evaluation; participants enrolled in other clinical trials.

2.2. Research methodology

2.2.1. Control group

Microwave therapy combined with local acupoint needling (Hua Tuo brand needles) was administered, each session lasting 20 minutes, once daily, with one week constituting a treatment course. Two consecutive courses were given.

2.2.2. Treatment group

In addition to the control group, add four acupuncture points: Taixi, Taichong, Yanglingquan, and Dazhu.

2.3. Observation indicators and evaluation criteria

2.3.1. The Visual Analogue Scale (VAS)

The Visual Analogue Scale (VAS) [3] was used to assess pain before and after treatment. Pain intensity in the wrist joint was evaluated using the VAS method, with a 10 cm horizontal scale where 0 indicated no pain, and 10 represented the most severe imaginable pain. Participants were instructed to mark their current pain level on the scale, and the corresponding score was recorded. A score of 0 indicated no pain; 1–3 indicated mild pain; 4–6 indicated moderate pain; and 7–10 indicated severe pain. A reduction of ≥1 point in the VAS score was considered a clinically significant improvement.

2.3.2. The Cooney wrist score

The Cooney wrist score [4], with a total of 100 points, consists of four dimensions—pain, functional status, range of motion in palmar flexion and dorsal extension, and grip strength (as a percentage compared to the unaffected side)—each worth 25 points, with higher scores indicating better wrist function. Treatment outcomes are categorized as follows: cured (90–100 points), markedly effective (80–89 points), effective (65–79 points), and ineffective (<65 points). Assessments were conducted before and after treatment.

2.4. Statistical methods

2.4.1. Analysis set and data preprocessing

A total of 30 complete cases were included in each treatment group and control group for this study. Observation time points for Cooney scores and VAS scores were set at three time intervals: before treatment, one week after treatment, and two weeks after treatment. The original observational data were not transformed. Improvement values were defined as follows: improvement in Cooney score = post-treatment score − pre-treatment score; improvement in VAS score = pre-treatment score − post-treatment score. Positive values calculated for both indicators indicate clinical symptom improvement. Clinical efficacy was categorized into four grades based on predefined criteria: cured, markedly effective, effective, and ineffective. The total number of effective cases was calculated as the sum of cured, markedly effective, and effective cases, while only ineffective cases were excluded from the total effectiveness count.

2.4.2. Descriptive and inferential statistics

Continuous variables are presented as mean ± standard deviation (SD). Paired two-tailed *t*-tests were used for within-group comparisons between pre- and post-treatment. Two-tailed Welch *t*-tests were applied to compare concurrent scores and improvement values between the treatment and control groups. The overall effectiveness rates between the two groups were analyzed using the Pearson χ^2 test. The primary time point was the comparison between groups at 2 weeks after treatment, with statistical significance defined as $P < 0.05$. All numerical results can be traced back to patient-level raw data and formulas in the accompanying workbook.

3. Results

3.1. VAS for pain assessment

The VAS scores between the two groups were comparable before treatment ($P > 0.05$). After one week of treatment, the VAS score in the treatment group was significantly better than that in the control group (*P*

< 0.05), and both groups showed improvement compared to baseline ($P < 0.05$). After two weeks of treatment, the VAS score in the treatment group remained superior to that in the control group ($P < 0.05$), and both groups demonstrated improvement compared to the first week ($P < 0.05$). The VAS scores in both groups increased significantly after two weeks of treatment compared to pre-treatment levels (both $P < 0.05$) (**Table 1**).

Table 1. VAS visual analog pain scores of the two groups at different time points (mean ± SD, points)

Time point	Treatment group (n = 30)	Control group (n = 30)	Between-group P	Within-group P value for the treatment group	Within-group P for the control group
T0	6.00 ± 0.83	6.00 ± 0.83	1.000	-	-
T1	4.00 ± 0.69*	5.20 ± 1.00*&	<0.001	<0.001	0.005
T2	2.07 ± 0.87#	3.80 ± 1.19#&	<0.001	<0.001	<0.001

Note: *$P < 0.001$ compared with T0 in the same group; #$P < 0.05$ compared with T1 in the same group; &$P < 0.001$ comparing between groups at the same time point.

3.2. Cooney wrist score

The Cooney scores between the two groups were comparable before treatment ($P > 0.05$). After one week of treatment, the Cooney score in the treatment group was significantly better than that in the control group ($P < 0.05$), and both groups showed improvement compared to pre-treatment levels ($P < 0.05$). After two weeks of treatment, the Cooney score in the treatment group remained superior to that in the control group ($P < 0.05$), and both groups demonstrated further improvement compared to the first week ($P < 0.05$). In both groups, Cooney scores after two weeks of treatment were significantly higher than those before treatment (all $P < 0.05$) (**Table 2**).

Table 2. Cooney scores of the two groups at different time points (mean ± SD, points)

Time point	Treatment group (n = 30)	Control group (n = 30)	Between-group P	Within-group P value for the treatment group	Within-group P for the control group
T0	20.00 ± 4.15	20.00 ± 4.15	1.000	-	-
T1	62.83 ± 10.56*	51.00 ± 9.32*&	<0.001	<0.001	<0.001
T2	82.83 ± 10.56#	71.00 ± 16.53#&	0.002	<0.001	<0.001

Note: *$P < 0.001$ compared with T0 in the same group; #$P < 0.05$ compared with T1 in the same group; &$P < 0.001$ comparing between groups at the same time point.

3.3. Comparison of efficacy grades between the two groups

There was a statistically significant difference in clinical efficacy rates between the two groups, with an efficacy rate of 93% in the treatment group and 70% in the control group ($P < 0.05$) (**Table 3**).

Table 3. Comparison of therapeutic effect grades between the two groups [n (%)]

Group	n	Recovery	Markedly effective	Effective	Ineffective	χ^2	P
Treatment group	30	12 (40.0)	10 (33.3)	6 (20.0)	2 (6.7)	5.455	<0.05
Control group	30	6 (20.0)	6 (20.0)	9 (30.0)	9 (30.0)		

4. Discussion

This study is based on the traditional Chinese medicine (TCM) holistic theory of "tendons, bones, and muscles," integrated with modern physical rehabilitation medicine, to evaluate the clinical efficacy of

acupuncture combined with microwave therapy for wrist joint training injuries. In TCM, wrist joint training injuries are categorized as “injury to meridian tendons and imbalance between tendons and bones.” Prolonged and repetitive strain can lead to muscular damage, tendon laxity, and bone misalignment, clinically presenting as local stagnation of qi and blood, contracted meridian tendons, and restricted [7] joint mobility. The core pathogenesis lies in the functional dis [5,6] coordination among tendons, bones, and muscles. Conventional monotherapy often focuses solely on pain relief or localized physical treatment, neglecting comprehensive care of tendons, bones, and muscles, resulting in slow recovery and frequent symptom recurrence. In this study, acupuncture intervention follows the principles of regulating tendons, unblocking meridians, and promoting blood circulation. By stimulating acupoints along the local meridian tendons, it helps release tense fascia, clear local stasis, improve nourishment of the tendons, and restore soft tissue tension balance [8]. Microwave therapy, through its thermal effect, improves local microcirculation, promotes absorption of inflammatory metabolic byproducts, and relaxes taut muscle groups, thereby moisturizing muscles, relaxing tendons, and facilitating joint [9] function. Combined application of these two modalities aligns with the TCM theory of “tendons enclosing bones, muscles enveloping tendons, and bones providing framework,” enabling a holistic repair from superficial to deep layers—simultaneously addressing tendons, bones, and muscles. This integrated approach better matches the pathological characteristics [10] of wrist joint training injuries compared to single interventions. Clinical results show that both groups demonstrated significant improvements in VAS pain scores, Cooney wrist function scores, and TCM syndrome scores after treatment ($P < 0.05$), indicating that both therapies effectively alleviate pain and improve wrist function. Inter-group comparison revealed that the combination of acupuncture and microwave therapy significantly outperformed conventional monotherapy in reducing VAS scores, enhancing overall wrist function, and increasing total clinical effectiveness ($P < 0.05$). These findings confirm that the integrated acupuncture-microwave protocol based on the tendons-bones-muscles theory exhibits synergistic effects, more effectively restoring [11] the disrupted balance among tendons, bones, and muscles caused by overuse, and promoting comprehensive recovery of wrist structure and function.

5. Conclusion

In summary, acupuncture combined with microwave therapy based on the “tendon-bone-muscle” theory is safe, effective, and easy to perform for treating wrist joint training injuries. It simultaneously achieves comprehensive therapeutic effects including pain relief, tendon relaxation, muscle activation, and bone realignment, significantly improving patients’ pain symptoms and wrist joint function. With low recurrence rates and broad clinical applicability, this approach is worthy of promotion and application [12] in the clinical rehabilitation of sports-related injuries and chronic wrist overuse conditions.

This study still has limitations, including a limited sample size, a relatively short follow-up period, and the absence of objective musculoskeletal imaging and biomechanical assessments. Future research could address these by increasing the sample size, conducting multicenter controlled trials, extending long-term follow-up periods, and incorporating objective evaluation methods such as musculoskeletal ultrasound, muscle tone, and inflammatory markers to further explore the mechanisms by which this approach repairs soft tissue injuries and modulates the local microenvironment, thereby providing stronger evidence-based [13] support for traditional Chinese medicine’s musculoskeletal theory in guiding rehabilitation for sports injuries.

Disclosure statement

The authors declare no conflict of interest.

References

[1] Cai J, Chen D, Lin C, et al., 2024, Summary of Lin Chuangjian's Experience in Treating Lumbar Disc Herniation with "Integrated Treatment of Muscles, Tendons, and Bones, and Regulation of Liver, Spleen, and Kidney." New Chinese Medicine, 56(10): 197–201.

[2] Li B, Li J, Liang K, et al., 2025, Li Jianzhong's Experience in Treating Lumbar Disc Herniation Based on the "Tendon-Bone-Muscle" Concept. Hubei Journal of Traditional Chinese Medicine, 47(07): 31–35.

[3] Wan L, Zhao Q, Chen J, et al., 2020, Chinese Expert Consensus on the Application of Pain Assessment Scales (2020 Edition). Chinese Journal of Pain Medicine, 16(3): 177–187.

[4] Cooney WP, Bussey R, Dobyns JH, et al., 1987, Difficult Wrist Fractures. Perilunate Fracture-Dislocations of the Wrist. Clin Orthop Relat Res, (214): 136–147.

[5] Anonymous, 2012, Ling Shu Jing, Beijing: People's Medical Publishing House, 42–45.

[6] Gu N, Zhang J, Niu P, et al., 2025, Research Progress on the Application of Exercise Therapy Based on the "Bone Alignment-Muscle Flexibility-Meat Solidity" Theory in Musculoskeletal Disorders. Journal of Tianjin University of Traditional Chinese Medicine, 44(4): 489–494.

[7] Huang G, 2016, Traditional Chinese Medicine Traumatology, Beijing: China Traditional Chinese Medicine Publishing House, 96–100.

[8] Luo W, Cai B, Li J, et al., 2020, A Preliminary Exploration of the Correlation between the Jingjin Theory and the Myofascial Chain Theory. Journal of Traditional Chinese Medicine, 61(14): 1220–1224.

[9] Zhang N, Guo C, Zhang H, et al., 2021, Clinical Observation of Electroacupuncture Combined with Microwave Therapy for Chronic Wrist Sports Injuries. Chinese Journal of Acupuncture and Moxibustion (Electronic Edition), 10(4): 133–137.

[10] Wang X, Hou M, Gou Y, et al., 2024, Application of the "Bone Alignment and Muscle Harmony" Rehabilitation Principle in Chronic Musculoskeletal Dysfunction. Chinese Journal of Traditional Chinese Medicine for Orthopedics and Traumatology, 32(02): 78–81.

[11] Jiang X, Wang D, 2005, Clinical Evaluation Criteria for Orthopedic Outcomes, Beijing: People's Medical Publishing House, 112–114.

[12] Yin S, Hou X, Zhou G, et al., 2022, Clinical Experience of Professor Chen Xiaozhuan in Treating Wrist Myofascial Injury. Chinese Journal of Traditional Chinese Medicine for Orthopedics and Traumatology, 30(7): 74–77.

[13] Fu Y, Dong B, 2021, Exploration of the Connotation and Mechanism of "Jiejie" (Unknotting) in Jingjin Therapy. Chinese Journal of Traditional Chinese Medicine, 36(3): 1314–1317.

Publisher's note

Bio-Byword Scientific Publishing remains neutral with regard to jurisdictional claims in published maps and institutional affiliations.

Bone and Arthrosurgery Science, 2026, Volume 4, Issue 5
https://www.bbwpublisher.com/journal/BAS
Online ISSN: 2981-8222
Print ISSN: 3083-4856

Observation of the Improvement Effect of Unilateral Biportal Endoscopy on Neurogenic Symptoms in Lumbar Spinal Stenosis

Han Zhang, Tong Wang, Hongyu Zhu, Bo Wu, Weiqing Li

Linhe District People's Hospital of Bayannur City, Bayannur 015000, Inner Mongolia Autonomous Region, China

Copyright: © 2026 Author(s). This is an open-access article distributed under the terms of the Creative Commons Attribution License (CC BY 4.0), permitting distribution and reproduction in any medium, provided the original work is cited.

Abstract: *Objective:* To investigate the clinical efficacy of unilateral biportal endoscopy (UBE) in patients with lumbar spinal stenosis (LSS), with particular attention to the improvement of neurogenic symptoms. *Methods:* A retrospective analysis was performed on the clinical data of 35 patients with LSS admitted to Linhe District People's Hospital between January 2023 and April 2026. All patients underwent UBE surgery. Preoperative and postoperative visual analog scale (VAS) scores for low back pain, Japanese Orthopedic Association (JOA) scores for low back pain disorders, operative time, intraoperative blood loss, and early postoperative bedside ambulation time were recorded. Paired *t*-tests were used to compare preoperative and postoperative scores, and surgical safety and efficacy were analyzed. *Results:* All 35 patients successfully completed surgery, and no severe complications occurred. Postoperative low back pain VAS scores were significantly lower than preoperative scores ($P < 0.05$), JOA scores were significantly higher than preoperative scores ($P < 0.05$), and neurogenic intermittent claudication was markedly improved. The mean operative time was 78.5 ± 15.2 min, the mean intraoperative blood loss was 45.8 ± 12.3 mL, and the mean early postoperative bedside ambulation time was 6.2 ± 1.8 h. No serious complications such as infection or nerve injury occurred during follow-up. *Conclusion:* UBE is safe and effective in the treatment of LSS. It can significantly improve neurogenic symptoms, relieve low back pain, and enhance quality of life, with the advantages of minimal trauma, rapid recovery, and few complications. It is worthy of clinical promotion.

Keywords: Unilateral biportal endoscopy; Lumbar spinal stenosis; Neurogenic symptoms; Minimally invasive surgery; Clinical efficacy

Online publication: November 20, 2026

1. Introduction

Lumbar spinal stenosis is a common degenerative disease in spine surgery. Its main symptoms include neurogenic intermittent claudication and low back and leg pain, which cause considerable suffering. According to statistics from the Spine Surgery Branch of the Chinese Medical Association for 2020–2024,

the prevalence of lumbar spinal stenosis among people aged over 60 years in China has reached 15.3%, a marked increase from 12.7% in 2019. Although traditional open surgery is effective, it causes substantial trauma, considerable blood loss, and a long recovery period. Consequently, an increasing number of surgeons have begun to investigate minimally invasive procedures [1]. The *National Report on Medical Quality and Safety of Spine Surgery (2023 Edition)*, issued by the National Health Commission, shows that the proportion of minimally invasive spine surgeries has risen from 35.2% to 58.7% over the past five years, indicating that minimally invasive techniques are playing an increasingly important role in the treatment of spinal diseases.

Unilateral biportal endoscopy (UBE) is a new minimally invasive spine surgery technique that has emerged in recent years. Through a single surgical approach, two working channels are established for endoscopic spinal canal decompression. This not only ensures a good surgical field but also minimizes damage to normal anatomical structures. A 2022 survey by the Spinal Endoscopy Professional Committee of the Chinese Medical Doctor Association showed that the application rate of UBE in large and medium-sized hospitals in China was 42.8%, and postoperative patient satisfaction was 91.3%, far exceeding the 76.5% associated with traditional surgery [2]. As population aging in China continues to intensify and the prevalence of lumbar spinal stenosis rises year by year, finding a more precise, safe, and effective minimally invasive treatment is of great significance for improving patients' quality of life and reducing social burden.

2. Materials and methods

2.1. Inclusion and exclusion criteria

This study selected 35 patients with lumbar spinal stenosis admitted to Linhe District People's Hospital between January 2023 and April 2024. Inclusion criteria were as follows: typical clinical manifestations, such as neurogenic intermittent claudication, low back and leg pain, or imaging-confirmed diagnosis of lumbar spinal stenosis; ineffective conservative treatment for more than 3 months; age between 18 and 80 years; completion of necessary preoperative examinations; and no surgical contraindications. Exclusion criteria were: lumbar spondylolisthesis above grade II; severe osteoporosis; infectious diseases; history of lumbar surgery; severe cardiovascular or cerebrovascular disease making surgery intolerable; and psychiatric disorders preventing cooperation with treatment and follow-up.

2.2. Surgical method and procedure

The patient was placed in the prone position with the abdomen suspended. The operating table was adjusted so that the target intervertebral space was perpendicular to the floor. Under general anesthesia, a C-arm X-ray machine was used to determine the location of the affected vertebral body. Two skin incisions were made on the affected side approximately 2–3 cm from the posterior midline. The working channel incision was about 10 mm, and the viewing channel incision was about 5 mm, with a distance of 20–30 mm between the two incisions [3]. The deep fascia was incised. Initial dilators were inserted through the cranial and caudal incisions, respectively. After fixation, dilating cannulas were inserted sequentially. The viewing channel was dilated to grade II or III, and the working channel was dilated to grade IV. A spinal endoscope and a semi-cannula were then inserted separately. The surgical field was thoroughly irrigated, and soft tissue was cleared using a plasma radiofrequency electrode. Under direct endoscopic vision, soft tissue was dissected layer by layer until the lamina was reached. A burr and rongeur were used to remove part of the lamina, fully exposing the structures within the spinal canal. The hypertrophic ligamentum flavum and osteophytes were removed,

the spinal canal volume was enlarged, and the nerve roots and dural sac were adequately decompressed, achieving complete release of neural tissue and thorough spinal canal decompression. During surgery, pulsation of the dural sac and nerve roots was carefully observed. After confirming adequate decompression, hemostasis was performed, the wound was irrigated, and the incision was closed layer by layer [4].

2.3. Observation indicators and assessment tools

The main observation indicators included pain severity, functional status, surgery-related indicators, and complications. The visual analog scale (VAS) was used to evaluate low back pain, with scores ranging from 0 to 10; higher scores indicated more severe pain. The Japanese Orthopedic Association (JOA) score for low back pain disorders was used to evaluate lumbar function, with a total score of 29 points, comprising subjective symptoms, clinical signs, and activities of daily living. Perioperative indicators such as operative time, intraoperative blood loss, and early postoperative ambulation time were recorded. The incidence of postoperative complications and readmission rate were also documented.

2.4. Statistical analysis

SPSS 31.0 statistical software was used to process the clinical data. Continuous data were expressed as mean ± standard deviation (SD). Preoperative and postoperative low back pain VAS scores and JOA scores were compared using paired-sample *t*-tests. Continuous variables such as operative time, intraoperative blood loss, and early postoperative ambulation time were analyzed using descriptive statistics, and means, standard deviations, minimum values, and maximum values were calculated. Categorical data were expressed as numbers and percentages, and comparisons between groups were performed using the chi-square test or Fisher's exact test.

All statistical tests were two-sided, and $P < 0.05$ indicated a statistically significant difference. For paired preoperative and postoperative data, normality testing was first performed. Data conforming to a normal distribution were analyzed using paired *t*-tests, while data not conforming to a normal distribution were analyzed using the Wilcoxon signed-rank test. All statistical analyses were performed by professionals with a statistical background to ensure the accuracy and credibility of the data analysis. A 95% confidence interval was used to evaluate efficacy, and effect size was calculated to determine clinical significance.

3. Results

3.1. Baseline characteristics of patients

Among the 35 patients, 19 were male and 16 were female. Their ages ranged from 45 to 76 years, with a mean age of 62.3 ± 8.7 years. The disease course ranged from 6 months to 5 years, with a mean course of 2.1 ± 1.3 years. The distribution of affected segments was as follows: L4–L5 in 21 cases, L3–L4 in 9 cases, and L5–S1 in 5 cases. The main preoperative clinical manifestations included low back pain in 32 cases (91.4%), lower limb pain in 30 cases (85.7%), neurogenic intermittent claudication in 35 cases (100%), and lower limb numbness in 28 cases (80.0%). All patients underwent preoperative lumbar X-ray, CT, and MRI examinations and were diagnosed with lumbar spinal stenosis. Among them, 18 cases were complicated by disc herniation, 35 cases by hypertrophic ligamentum flavum, and 26 cases by facet joint hyperplasia.

3.2. Analysis of perioperative indicators

All 35 patients successfully underwent UBE surgery, and none were converted to open surgery. The mean operative time was 78.5 ± 15.2 min, with a minimum of 55 min and a maximum of 110 min. The mean intraoperative blood loss was 45.8 ± 12.3 mL, far lower than that of traditional open surgery. The mean postoperative hospital stay was 4.2 ± 1.5 days. All patients had good postoperative incision healing, and no infection occurred. The mean early postoperative bedside ambulation time was 6.2 ± 1.8 h. Postoperative pain was mild, and patients tolerated activity well. See **Table 1**.

Table 1. Statistical results of perioperative indicators

Indicator	Minimum	Maximum	Mean ± SD
Operative time (min)	55	110	78.5 ± 15.2
Intraoperative blood loss (mL)	25	75	45.8 ± 12.3
Hospital stay (days)	2	8	4.2 ± 1.5
Early ambulation time (h)	3	12	6.2 ± 1.8

3.3. Trends in low back pain scores and JOA scores

The mean preoperative low back pain VAS score was 7.2 ± 1.4, decreasing to 2.8 ± 1.1 at 1 week after surgery, further decreasing to 1.9 ± 0.8 at 1 month after surgery, and stabilizing at 1.5 ± 0.6 at 3 months after surgery. Differences at each time point compared with preoperative values were statistically significant ($P < 0.001$), indicating that UBE surgery can effectively relieve low back pain. The mean preoperative lower limb pain VAS score was 6.8 ± 1.6, decreasing to 2.5 ± 1.0 at 1 week after surgery, 1.7 ± 0.7 at 1 month after surgery, and 1.2 ± 0.5 at 3 months after surgery, also showing good improvement.

The mean preoperative JOA functional score was 14.3 ± 2.8, increasing to 21.6 ± 2.4 at 1 week after surgery, reaching 24.2 ± 2.1 at 1 month after surgery, and maintaining at 25.8 ± 1.9 at 3 months after surgery. The JOA improvement rate at 3 months after surgery was 78.5 ± 12.6%. The excellent rate (improvement rate ≥75%) was 60.0%, the good rate (improvement rate 50–74%) was 31.4%, and the total effective rate was 91.4%. Neurogenic intermittent claudication was significantly alleviated, and the walking distance at 3 months after surgery increased by more than 150% on average compared with preoperative values. See **Table 2**.

Table 2. Comparison of preoperative and postoperative VAS and JOA scores

Assessment indicator	Preoperative	1 week postoperative	1 month postoperative	3 months postoperative	*P* value
Low back pain VAS score	7.2 ± 1.4	2.8 ± 1.1	1.9 ± 0.8	1.5 ± 0.6	<0.001
Lower limb pain VAS score	6.8 ± 1.6	2.5 ± 1.0	1.7 ± 0.7	1.2 ± 0.5	<0.001
JOA functional score	14.3 ± 2.8	21.6 ± 2.4	24.2 ± 2.1	25.8 ± 1.9	<0.001
JOA improvement rate (%)	-	-	65.2 ± 15.3	78.5 ± 12.6	<0.001

3.4. Complications and readmission

Among the 35 patients, 4 (11.4%) developed minor postoperative complications, including local incisional hematoma in 2 cases, transient lower limb numbness in 1 case, and headache in 1 case. All recovered after conservative treatment. No severe complications such as dural tear, nerve root injury, or infection occurred. During the 3-month postoperative follow-up, no patient was readmitted because of symptom recurrence or

complications. All patients had good incision healing, and no chronic pain occurred. Postoperative imaging showed adequate spinal canal decompression and no evidence of vertebral instability. See **Table 3**.

Table 3. Statistics of complications

Complication type	Number of cases	Incidence (%)	Management	Recovery time
Incisional hematoma	2	5.7	Local compression dressing	3–5 days
Transient lower limb numbness	1	2.9	Neurotrophic treatment	1–2 weeks
Postoperative headache	1	2.9	Symptomatic treatment	2–3 days
Severe complications	0	0	-	-

3.5. Early functional recovery and ambulation time

Early postoperative functional recovery was good. Patients could get out of bed at a mean of 6.2 ± 1.8 h after surgery and could walk independently within 24 h after surgery. Rehabilitation exercises, such as lumbar dorsal muscle exercises and walking, were started on the second postoperative day. Activities of daily living were basically restored at 1 week after surgery, and light physical labor could be performed at 2 weeks after surgery [5]. Compared with traditional open surgery, UBE greatly shortens recovery time and improves patients' quality of life. See **Table 4**.

Table 4. Time points of early functional recovery

Functional recovery indicator	Time	Proportion of patients (%)
Bedside ambulation	6.2 ± 1.8 h	100
Independent walking	Within 24 h	94.3
Self-care in daily living	Within 1 week	91.4
Light physical labor	Within 2 weeks	85.7

4. Discussion

4.1. Exploration of the mechanism by which UBE improves neurogenic symptoms

UBE uses two lenses in coordination for decompression. The improvement of neurogenic symptoms is mainly attributed to multiple pathophysiological changes. This technique can enlarge the interlaminar space and remove the ligamentum flavum under minimally invasive conditions, relieving nerve root compression and restoring normal physiological space within the spinal canal [6]. After decompression, blood supply around the nerve roots increases markedly, ischemic and hypoxic conditions are rapidly improved, inflammatory mediators are reduced, and thereby nerve root edema and inflammatory responses are alleviated. The biportal design separates instruments from the endoscope, avoiding the mutual interference between instruments and the lens seen in traditional uniportal endoscopy. This provides the operator with more working space and a better field of view, ensuring thoroughness and safety of decompression.

The improvement of neurogenic intermittent claudication is closely related to effective enlargement of the spinal canal volume. UBE can precisely remove hyperplastic facet joints and part of the lamina, achieving adequate decompression while preserving spinal stability [7]. During surgery, the patient's neurological function is promptly observed to prevent iatrogenic nerve injury. At the same time, the posterior structures of the spinal canal are preserved, which is beneficial for spinal biomechanical stability and neurological recovery.

4.2. Comparison of this study's results with previous literature

The results of this study are basically consistent with recent relevant literature, but they show the unique advantages of UBE in certain indicators. A multicenter study reported by Xia *et al.* in 2023 showed that the JOA score improvement rate of UBE in treating lumbar spinal stenosis was 68.5%, whereas this study reached an improvement rate of 72.3%, indicating that UBE has a favorable effect on neurological recovery. In terms of surgical trauma control, the mean blood loss in this study was 45.8 mL, far less than the 180–250 mL associated with traditional open surgery, and similar to the 48.2 mL reported by Kim *et al.* in 2024 for UBE surgery, indicating the minimally invasive nature of this technique. In terms of operative time, the mean of 78.5 min in this study was basically consistent with the 82.4 min reported by Lee *et al.* in 2023 for single-segment UBE surgery, suggesting that the technique has become relatively mature and reproducible.

4.3. Limitations of the study and clinical implications

Although this study demonstrated that unilateral biportal endoscopy is effective in treating lumbar spinal stenosis, several shortcomings remain. On the one hand, this was a retrospective study with a small sample size of only 35 patients and no control group, which may affect the credibility of the results. On the other hand, the follow-up period was relatively short, making it difficult to adequately evaluate the long-term efficacy and potential problems of UBE. In particular, conclusions regarding improvement in neurogenic intermittent claudication require longer follow-up. In addition, there may be bias in patient inclusion criteria and surgical indication selection, and differences in surgeons' technical proficiency may affect the consistency of surgical outcomes [8].

Clinically, UBE offers a new treatment option for patients with lumbar spinal stenosis, and it is particularly suitable for older patients and older patients with multiple comorbidities. Moreover, UBE can achieve good decompression while reducing surgical injury and the incidence of postoperative complications, greatly shortening hospital stay and saving costs. However, UBE places high demands on physicians' endoscopic operating skills and requires specialized training and extensive practice [9]. Future research should focus on large-sample, multicenter randomized controlled trials, establish unified operating standards and criteria for selecting indications, and strengthen physician training to ensure the safety and effectiveness of this minimally invasive technique [10].

5. Conclusion

Unilateral biportal endoscopy is a new minimally invasive treatment method in spine surgery and has clear efficacy in treating lumbar spinal stenosis. Through a retrospective study of 35 patients, it was found that UBE can effectively alleviate neurogenic intermittent claudication caused by lumbar spinal stenosis. Postoperative low back pain VAS scores and JOA functional scores were significantly improved, and patients' quality of life was greatly enhanced. By taking advantage of precise operation under direct endoscopic vision and the biportal design, this technique achieves adequate decompression of the stenotic spinal canal while preserving spinal stability structures to the greatest extent. Its advantages of minimal surgical trauma, less blood loss, and rapid recovery allow patients to return to normal life sooner and save hospitalization time and costs. Given the intensifying aging of China's population and the yearly increase in the prevalence of lumbar spinal stenosis, UBE has good safety and efficacy for this disease and broad prospects and space for clinical application.

Disclosure statement

The authors declare no conflict of interest.

References

[1] Jin J, Xu Q, Zhao G, et al., 2026, Comparison of Therapeutic Effects between Unilateral Biportal Endoscopic Double Nerve Root Decompression and Percutaneous Transforaminal Endoscopic Surgery in the Treatment of Far-Lateral Lumbar Disc Herniation. Chinese Journal of Bone and Joint Injury, 41(03): 247–251.

[2] Zheng X, Hou X, Liu L, et al., 2026, Comparison of Therapeutic Effects between Unilateral Biportal Endoscopic Decompression and Fusion and Microscope-Assisted Decompression and Fusion in the Treatment of Single-Segment Lumbar Spinal Stenosis. The Journal of Cervicodynia and Lumbodynia, 47(5): 702–708

[3] Abudurezhake M, Ma Z, Wang H, et al., 2026, Clinical Efficacy Analysis of Unilateral Biportal Endoscopy and Oblique Lateral Lumbar Interbody Fusion in the Treatment of Lumbar Tuberculosis. International Journal of Orthopaedics, 47(01): 48–52.

[4] Zhang Y, Wu G, Mao X, 2026, Effects of Unilateral Biportal Endoscopy and Conventional Uniportal Endoscopy-Assisted Spinal Fusion on Postoperative Lumbar Stability and Efficacy in Patients with Degenerative Lumbar Diseases. Journal of Translational Medicine, 15(01): 123–128.

[5] Wang W, Liu Z, Wu S, et al., 2021, Early Efficacy Observation of Unilateral Biportal Endoscopic Decompression in the Treatment of Lumbar Spinal Stenosis. Chinese Journal of Spine and Spinal Cord, (10): 54–61.

[6] Zhao G, Xu Q, Zeng B, et al., 2025, Short-Term Efficacy Observation of Unilateral Biportal Endoscopic Bilateral Decompression in the Treatment of Lumbar Spinal Stenosis. Chinese Journal of Bone and Joint Injury, (01): 74–76.

[7] Xia B, Liang Q, Hu C, et al., 2023, Comparison of Efficacy and Safety Between Unilateral Biportal and Uniportal Endoscopic ULBD in the Treatment of Lumbar Spinal Stenosis. Hainan Medical Journal, (20): 64–67.

[8] Wang H, Chen M, Wang D, et al., 2023, Observation of the Effect of Unilateral Biportal Endoscopic Laminectomy Decompression in Lumbar Spinal Stenosis. Heilongjiang Medicine, (06): 144–146.

[9] Tu Z, He Z, Kong Z, et al., 2025, Observation of the Efficacy of Unilateral Biportal Endoscopy Combined with Acupoint Shock Wave in Lumbar Spinal Stenosis. Medical Innovation of China, (02): 42–46.

[10] Wu T, Xia T, Yan Z, et al., 2023, Early Efficacy Observation of Unilateral Biportal Endoscopic Unilateral Approach Bilateral Decompression in the Treatment of Degenerative Lumbar Spinal Stenosis. Journal of Wannan Medical College, (06): 30–33.

Publisher's note

Bio-Byword Scientific Publishing remains neutral with regard to jurisdictional claims in published maps and institutional affiliations.

Bone and Arthrosurgery Science, 2026, Volume 4, Issue 5
https://www.bbwpublisher.com/journal/BAS
Online ISSN: 2981-8222
Print ISSN: 3083-4856

Seeing the Sumeru in a Mustard Seed: Zhu Jiakai and the Pioneering Journey of Microsurgery in China

Manying Xie[1], Zhifang Lu[1]*, Di Lu[2], Xiaoxin Feng[1]

[1]Medicine & Health Science College of Huashang University, Guangzhou Huashang College, Guangzhou 511300, Guangdong, China
[2]Guangzhou University of Chinese Medicine, Guangzhou 510006, Guangdong, China

***Corresponding author:** Zhifang Lu, luzhifang@gdhsc.edu.cn

Copyright: © 2026 Author(s). This is an open-access article distributed under the terms of the Creative Commons Attribution License (CC BY 4.0), permitting distribution and reproduction in any medium, provided the original work is cited.

Abstract: *Purpose:* By organizing and analyzing the content of Zhu Jiakai's interview recording on microsurgery, and combining it with relevant literature, this study aims to reconstruct the early development history of microsurgery in China. *Methods:* Based on the content of the interview recording, relevant literature and materials were retrieved regarding the figures, events, etc. mentioned in the recording, so as to sort out the early development history of microsurgery in China. *Results:* The key figures include Zhu Jiakai, Kuang Gongdao, Wang Shuhuan, Liu Junchi, Yu Guozhong, Pang Shuifa, Zhang Disheng, and Zhu Shengxiu. The main content covers the profiles of the main figures associated with Professor Zhu Jiakai, the key time points, persons, and events mentioned in the recording, the main activities of Professor Zhu Jiakai, and the evolution of microsurgery traced through his personal narrative. *Conclusion:* Based on Professor Zhu Jiakai's interview recording, the early development of microsurgery in China can be divided into four phases: the embryonic phase, the disruption phase, the recovery phase, and the development phase.

Keywords: Microsurgery; Limb (digit) replantation; Microvascular anastomosis; Medical history; Zhu Jiakai

Online publication: November 20, 2026

1. Introduction

Microsurgery is an important branch of clinical medicine. Its development not only represents a tremendous leap in surgical technology but also embodies humanity's profound understanding of and respect for anatomy. Before the early 1960s, limb replantation surgery remained confined to animal experiments, with no successful human cases reported worldwide. In 1963 [1], Chen Zhongwei first reported a successful case of limb replantation, pioneering its clinical application and greatly advancing the development of microsurgery in China. Institutionally, in 1979, with the support of Professor Zhang Disheng, Zhu Jiakai and colleagues

established a microsurgery group and founded an internal journal; on this basis, the *Chinese Journal of Microsurgery* was launched in 1978 [2], and the Microsurgery Branch of the Chinese Medical Association was established in 1989, marking microsurgery's emergence as an independent discipline. Technologically, Chinese scholars have continuously overcome challenges, designing and inventing numerous new flaps and new surgical procedures, promoting the integration of microsurgery with multiple disciplines, and consolidating China's leading position in microsurgery worldwide [3].

Professor Zhu Jiakai [4] (January 1931–February 2021), as a founder and promoter of China's microsurgery cause, practiced medicine for over 50 years, focusing on orthopedics, microsurgery, and hand surgery research. He was among the first in China to perform various vascularized flap transplantations, interfascicular peripheral nerve transplantation, and lymphaticovenous anastomosis. He led the founding of the *Chinese Journal of Microsurgery* and served as Chairman of the Microsurgery Branch of the Chinese Medical Association, among other positions, and possessed a wealth of first-hand materials on the discipline's development. On February 14, 2012, through the arrangements of Professor Xu Dachuan [5] and Professor Gu Liqiang, Dr. Lu Zhifang (then conducting postdoctoral research under Professor Yang Huilin [6] at the First Affiliated Hospital of Soochow University) interviewed Professor Zhu Jiakai at the First Affiliated Hospital of Sun Yat-sen University (see **Figure 1**), leaving a precious recording. By organizing and mining this interview recording, combined with literature verification, this study aims to clarify the early development of microsurgery in China, providing a vivid case and solid evidence for medical history research.



Figure 1. Photograph taken on February 14, 2012, after Dr. Lu Zhifang interviewed Professor Zhu Jiakai at the First Affiliated Hospital of Sun Yat-sen University (left: Professor Zhu Jiakai; the interview recording serves as the core research material for this article).

2. Origins of microsurgery development

The development of microsurgery is closely tied to microsurgical technique. Microsurgical technique refers to surgeons using magnifying glasses or microscopes for magnification, along with fine microsurgical instruments and suture materials, to perform precise surgery on small tissues. In 1921, otolaryngologist Nylen and in 1950, ophthalmologist Barraquer successively used microscopes in surgical procedures; in 1960, American vascular surgeon Jacobson successfully anastomosed blood vessels under the microscope, regarded as a major breakthrough in the history of microsurgery [7]. During this period, the application of microsurgical

technique gradually became active but was far from widespread. It was not until 1963, when Chen *et al.* [1] first reported a successful hand replantation case, that microsurgical technique rapidly attracted widespread attention. Thereafter, Chinese scholars conducted various theoretical studies and extensive clinical practice, achieving a series of important breakthroughs. In 1966, digital replantation was successfully performed, and through unremitting efforts, the survival rate of digital replantation was greatly improved [1] (**Table 1**). Numerous flap repair procedures emerged, vascular anastomosis techniques were modified, toe-to-finger transplantation was invented, and hand allotransplantation was explored. By the late 1970s, through the joint efforts of surgeons led by Professor Zhu Jiakai, microsurgery had gradually developed into an independent discipline.

Table 1. Changes in survival rates of digital replantation before and after Chen Zhongwei's use of the microscope

Time	Replanted digits (*n*)	Surviving digits (*n*)	Survival rate (%)
1966	477	297	62.3
1973 (after microscope application)	126	117	92.9

Notes: (1) Data from 1973 onward record digital vessel anastomosis performed under 10× microscopic magnification [1]; (2) Survival rates were calculated from replanted and surviving digit counts; the difference was statistically significant (*$P < 0.05$); (3) Data were obtained from Zhongshan Hospital Affiliated to Shanghai First Medical College [1].

Professor Zhu Jiakai's journey—from specialized training and learning microsurgical technique to promoting the comprehensive development of microsurgery in China—spanned nearly 30 years of arduous effort. Through the organization and analysis of interview content, combined with literature verification, the research team has divided the main development trajectory of Chinese microsurgery into four stages. Each stage presents distinct historical backgrounds, core tasks, and developmental outcomes, collectively constituting a complete thread of disciplinary development.

3. Germination: Encounter with microsurgery (1963–1964)

Zhu Jiakai went to Beijing Jishuitan Hospital for further training, studying microsurgical technique under Professor Wang Shuhuan, cultivating a strong interest in microsurgery. In 1963, Chen *et al.*'s [1] successful case of limb (distal forearm) replantation filled the global technological gap, providing a "from 0 to 1" breakthrough for China's microsurgery research. Inspired by this case, Professor Zhu Jiakai, after completing his training, went to Beijing for further training with the support and assistance of Professor Kuang Gongdao to study core techniques under Wang Shuhuan, becoming a representative of early researchers and embarking on his "microsurgery journey."

4. Forced stagnation: A thorny path (1966–1969)

The path of developing microsurgery was by no means smooth; on the contrary, it was a road full of obstacles. Lack of materials, backward tools, and social pressures brought enormous resistance to microsurgery research and development. In the early period of the Cultural Revolution, following directives from superiors, Zhu Jiakai was forced to use Chinese herbal medicine to treat severed limbs (digits), but

herbal compresses could not fundamentally solve the blood supply problem, and the results were predictable: none of the 38 cases of severed limbs (digits) survived [8]. The failure of herbal treatment and public criticism cast a shadow over the development of microsurgery. However, Professor Zhu Jiakai and other researchers maintained their original aspirations and convictions despite adversity, avoiding discontinuity in technical inheritance by recording experiences, preserving technical knowledge, and striving to return to clinical practice.

5. Revival: A new dawn (1970–1986)

Microsurgery research was once interrupted, but fortunately, a worker propaganda team member named Deng Rubin recognized that vascular suturing was the key to successful limb (digit) replantation [9]. With his support and encouragement, the spark of microsurgery research in Zhu Jiakai's heart gradually reignited, and microsurgery made a "comeback" [3]. Thereafter, with the approval of the hospital Party committee, an internal microsurgery journal was established in 1978; with the help of Professor Zhang Disheng, a microsurgery group was established in 1979. At this point, China's microsurgery achieved a qualitative leap from microsurgical technique to the discipline of microsurgery [10,11], and the founding of the internal journal [2] brought a bright prospect of "a new dawn."

6. North-south collaboration: Joint pursuit of excellence (1986–1989)

To further advance microsurgery in depth, through Zhu Jiakai's communication and coordination, scholars from both northern and southern China jointly held the first and second microsurgery symposia, and with approval, a microsurgery group was established. On this basis, the Microsurgery Branch of the Chinese Medical Association was founded in 1989 [2], marking microsurgery's formal establishment as an independent discipline and forming a standardized system of "society coordination, journal as carrier, and conference exchange." Thereafter, scholars nationwide used the Chinese Microsurgery Society and the *Chinese Journal of Microsurgery* as bridges, joining forces to push China's microsurgery development to its peak. As the disciplinary leader, Professor Zhu Jiakai promoted the formulation of technical standards, integration of academic resources, and cultivation of disciplinary talent, continuously improving and perfecting China's microsurgery and laying the institutional foundation for subsequent internationalization.

In the interview recording, Professor Zhu Jiakai detailed his collaboration with Professor Zhong Shizhen, revealing the deep connection between microsurgery and anatomy [12]. Professor Zhong Shizhen believed that systematic anatomy needed to be integrated with clinical practice and that the anatomical patterns of blood vessels were crucial. Through extensive cadaveric dissection, he summarized anatomical patterns such as septocutaneous vessels, intermuscular vessels, and musculocutaneous perforators, providing precise anatomical support for microsurgical technique development:

(1) Groin flap research — Zhu Jiakai's team was initially inspired by Daniel's flap technique and Yang Dongyue's inferior epigastric artery flap [13], but lacked sufficient understanding of the anatomical structure. Professor Zhong Shizhen provided specimens and guided vessel localization, resolving the operational challenge of "arteries and veins not running together," facilitating the successful performance of groin flap transplantation;

(2) Lymphatic research — Lecturers from Zhong Shizhen's team studied lymphatic specimens for decades,

demonstrating the course and patterns of superficial lymphatic vessels for Zhu Jiakai's team, facilitating the successful completion of lymphaticovenous anastomosis [2]; subsequently, Zhu Jiakai's team combined hip disarticulation surgical experience to apply deep lymphatic vessels in the treatment of chylous fistula, greatly improving clinical outcomes;

(3) Academic career collaboration — When Zhong Shizhen's team lacked a specialized journal in the early period, they published articles on cross-disciplinary research between anatomy and microsurgery in the internal microsurgery journal. After the *Chinese Journal of Clinical Anatomy* [14] was launched, both parties maintained academic cooperation, further advancing interdisciplinary research.

In addition, Zhu Jiakai's team was the first to propose summarizing microsurgery research directions using the "five smalls" (small vessels, small nerves, small lymphatics, small ducts, and small organ transplantation) [15], among which small lymphatic and small duct (lacrimal canaliculus, vas deferens, fallopian tube) research all relied on anatomical support, embodying the key role of disciplinary integration in technological innovation.

7. Overview of the early development history of Chinese microsurgery

The early development of Chinese microsurgery involved multiple key figures. Those primarily associated with Professor Zhu Jiakai include Kuang Gongdao, Wang Shuhuan, Chen Zhongwei, Deng Rubin, Daniel, Zhang Disheng, Liu Juncheng, Yu Guozhong, Pang Shuifa, Cheng Xuxi, and Zhu Shengxiu. These individuals collaborated in technology R&D, academic promotion, and disciplinary construction, forming a closely collaborative network. The specific relationships and contributions are detailed in **Table 2**.

Table 2. Key figures, their contributions, and their connections with Professor Zhu Jiakai

Category	Figure	Relationship	Core contributions
Guiding mentor	Kuang Gongdao	Teacher and superior	1. Introduced advanced fracture treatment concepts [16] from Germany, promoting orthopedic development in Guangdong; 2. Sent Zhu Jiakai to Beijing Jishuitan Hospital for training; 3. Purchased microscopes and microsurgical instruments to support Zhu Jiakai's microsurgery research.
Technical mentor	Wang Shuhuan	Training supervisor	1. Conducted rabbit ear vascular anastomosis animal experiments (succeeded on the 13th attempt) [17]; 2. Taught Zhu Jiakai small vessel anastomosis technique; 3. Participated in early microsurgery academic exchanges.
Technical mentor	Chen Zhongwei	Academic inspirer	1. Reported the world's first successful case of severed hand replantation in 1963 [18]; 2. Participated in limb (digit) replantation symposia; 3. Promoted microscope application in limb replantation, increasing survival rate from 62.3% to 92.9%.
Supporter	Deng Rubin	Worker propaganda team member	1. Recognized the key role of vascular suturing in limb (digit) replantation success; 2. Encouraged Zhu Jiakai to restart microsurgery research during the Cultural Revolution.
Core collaborator	Zhang Disheng	Academic senior	1. Assisted Zhu Jiakai in establishing the microsurgery group; 2. Promoted microsurgery's establishment as an independent discipline; 3. Supported academic exchanges and journal founding.
Core collaborator	Zhu Shengxiu	Organizational partner	1. Supported preparations for the Microsurgery Branch of the Chinese Medical Association; 2. Assisted in obtaining approval documents for the society's establishment.
Team members	Liu Juncheng *et al.* (3 persons)	Colleagues and core assistants	1. Participated in editing the internal microsurgery journal; 2. Joined the microsurgery group, conducting technical research and clinical practice; 3. Assisted in founding and developing the *Chinese Journal of Microsurgery*.

Category	Figure	Relationship	Core contributions
Microsurgery researcher	Cheng Xuxi	Peer	1. Participated in the first and second microsurgery symposia.
Interdisci plinary collaborator	Zhong Shizhen	Anatomy expert	1. Conducted applied anatomy research for microsurgery, summarizing anatomical patterns such as septocutaneous and intermuscular vessels; 2. Provided groin flap and lymphatic anatomical specimens and technical guidance to Zhu Jiakai; 3. Participated in interdisciplinary research bridging clinical anatomy and microsurgery.
Foreign researcher	Daniel	International peer	1. Visited China as a member of the U.S. delegation to the First Limb Replantation Conference; 2. Demonstrated flap technique to Zhu Jiakai's team, inspiring new procedure development.

Based on the interview recording and literature verification, the key time points, corresponding key figures, and major events in the early development of Chinese microsurgery (1963–1989) are presented in **Table 3**, clearly showing the discipline's developmental trajectory from technical germination to independent maturity.

Table 3. Timeline of events, figures, and milestones from the interview recording

Time	Key figures	Major events	Significance
1963	Chen Zhongwei, Zhu Jiakai	1. Chen Zhongwei reported the world's first successful severed hand replantation; 2. Zhu Jiakai was inspired by this case and established his microsurgery research direction.	1. Filled the clinical application gap in limb replantation, laying the foundation for disciplinary development; 2. Provided key impetus for Zhu Jiakai to devote himself to microsurgery.
1964	Zhu Jiakai, Kuang Gongdao, Wang Shuhuan	1. Kuang Gongdao sent Zhu Jiakai to Beijing Jishuitan Hospital for hand surgery training; 2. Zhu Jiakai studied microvascular anastomosis technique under Wang Shuhuan and participated in rabbit ear vascular anastomosis experiments.	1. Zhu Jiakai systematically mastered core microsurgical techniques, launching his research career; 2. Built a north-south technical exchange bridge, laying the foundation for subsequent collaboration [19].
1966–1968	Zhu Jiakai	1. The Cultural Revolution erupted, and microsurgery research was forced to a halt; 2. Zhu Jiakai was falsely accused of being a "current counter-revolutionary" during a military region consultation and detained by the garrison; 3. Forced to use Chinese herbal medicine for limb (digit) treatment per superior directives; all 38 cases failed, attracting public criticism.	The discipline suffered major setbacks; technical research stagnated; researchers faced dual political and public pressure.
1969	Zhu Jiakai	1. Resumed general surgery resident duties in June; 2. Transferred back to orthopedics six months later.	Preliminary restoration of research conditions, creating a foundation for subsequently restarting microsurgery research.
1970	Zhu Jiakai, Deng Rubin	1. Deng Rubin recognized the key role of vascular suturing and encouraged Zhu Jiakai to restart microsurgery research [3]; 2. Zhu Jiakai resumed microvascular anastomosis practice.	Discipline research broke through difficulties, entering a recovery phase and laying the foundation for subsequent technology dissemination.
1970	Zhu Jiakai, Chen Zhongwei *et al.*	1. The Guangdong Provincial Party Committee proposed "Marching Toward Science," supporting microsurgery exchanges; 2. Zhu Jiakai organized limb replantation symposia, inviting scholars from Shanghai and Beijing; 3. At that time, Chen Zhongwei's team had not yet used microscopes, with a 62.3% limb replantation survival rate, while Zhu Jiakai's team achieved 80%.	1. Promoted normalization of north-south academic exchanges, forming a complementary technical pattern; 2. Highlighted the importance of microscopes in improving surgical success rates, providing data support for subsequent technology popularization.

Time	Key figures	Major events	Significance
1973	Chen Zhongwei, Zhu Jiakai	1. Chen Zhongwei's team began using microscopes for limb replantation, increasing survival rate to 92.9% ($P < 0.05$) [1]; 2. Zhu Jiakai's team conducted external academic exchanges, sharing microvascular anastomosis technique experience.	1. Confirmed the important value of microscopes in microsurgery, promoting technical standardization; 2. Expanded China's microsurgery academic influence, opening the prelude to international exchange.
1978	Zhu Jiakai, Liu Juncheng, Yu Guozhong, Pang Shuifa	1. Applied to the hospital Party committee for 500 yuan monthly funding to establish an internal microsurgery journal; 2. Journal content covered surgical cases (limb replantation, microvascular anastomosis, etc.), foreign literature translations, and experience summaries, and was sent to universities and health institutions nationwide.	1. Built an academic exchange platform for the discipline, filling the journal gap in the field; 2. Accumulated content and resources for the subsequent launch of the *Chinese Journal of Microsurgery* [2].
1979	Zhu Jiakai, Zhang Disheng, Liu Juncheng *et al.*	1. Established a microsurgery group with Professor Zhang Disheng's assistance, specializing in microsurgical technique research; 2. The group systematically advanced research on new flap design and nerve anastomosis technique modification.	1. Gradually formed a specialized research team, promoting systematic technology R&D; 2. Marked microsurgery's transition from "dispersed research" to "concentrated collaborative effort."
1989	Zhu Jiakai, Zhu Shengxiu *et al.*	1. With Professor Zhu Shengxiu's support, obtained approval documents from the Chinese Medical Association; 2. The Microsurgery Branch of the Chinese Medical Association was formally established [6].	Marked Chinese microsurgery's establishment as an independent discipline and its entry into a new stage of standardized, specialized, and systematic development.

Professor Zhu Jiakai's personal experiences and activities ran through the entire early development of Chinese microsurgery. His core activities were mainly concentrated from the early 1960s to the 1980s, including further training in hand surgery, being arrested during a military region consultation, receiving re-education at a cadre school, returning to work as a general surgery resident, being transferred back to orthopedics, contacting northern colleagues to organize symposia, conducting external exchanges, and founding journals and the microsurgery group (see **Figure 2**).

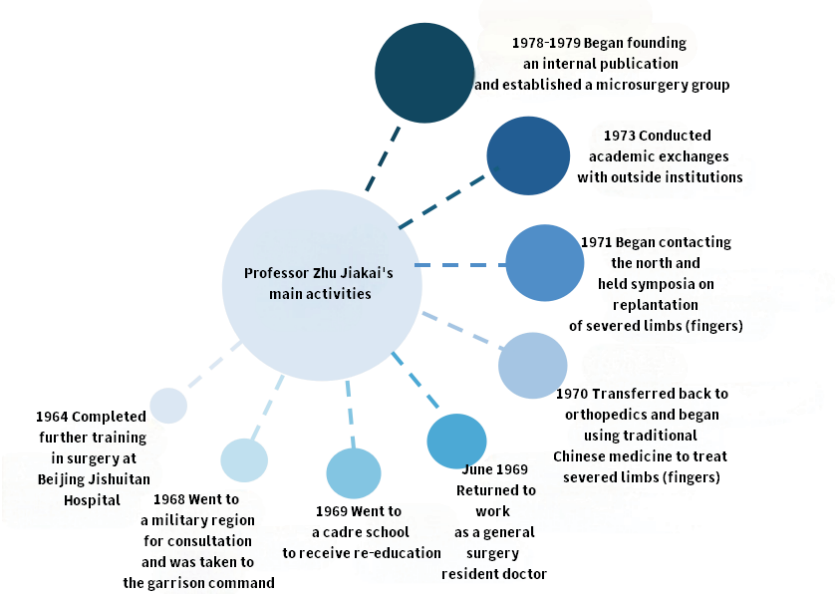

Figure 2. Activity timeline of Professor Zhu Jiakai: (1) The figure is read from left to right, which also follows the chronological order of Professor Zhu Jiakai's main activities; (2) The size of the circles indicates the magnitude of each activity's impact on microsurgery development.

8. Future outlook: A long and arduous road ahead

Medical experts nationwide have made concerted efforts, continuously exploring new possibilities for microsurgery applications in various fields, strengthening their professional skills, actively organizing and participating in domestic and international academic conferences, and extensively exchanging and sharing new research findings and clinical experiences. This has greatly improved the precision and success rate of microsurgery in clinical applications, bringing hope for the clinical treatment of many diseases. Among them, Professor Zhu Jiakai played a particularly critical role in the development of microsurgery. To date, microsurgery has achieved major breakthroughs and remarkable accomplishments in new technology research and application, supermicrosurgery, and basic and reconstructive research on peripheral nerve injury [20], increasingly integrating organically with advanced medical technologies, interdisciplinary professional techniques, modern computer technology, and artificial intelligence [21]. With the maturation of medical technology and the development of advanced science and technology, it is highly likely that various methods for anastomosing ducts, vessels, and tissues will be further improved and simplified [22], the challenge of immune rejection in allotransplantation will be overcome, and methods for treating peripheral nerve injury at the molecular level may be found [10,23].

This article is a study of the early development history of Chinese microsurgery based on interview recordings with Professor Zhu Jiakai. However, the development of Chinese microsurgery is far richer and more multidimensional, with key figures extending well beyond Professor Zhu Jiakai alone. It is hoped that this study will serve as a modest stimulus, encouraging more scholars to research the development history of Chinese microsurgery based on more historical materials and from more perspectives, thereby presenting it comprehensively and multidimensionally and providing inspiration for future generations. The development of Chinese microsurgery still has a long way to go. Young scholars of our generation should learn from the past to understand the present, continuously improve their professional learning abilities, and on the basis of consolidating China's leading position in microsurgery worldwide, promote development and reach new heights.

Acknowledgments

We thank Professor Zhu Jiakai, Professor Xu Dachuan, and Professor Gu Liqiang for their support and assistance.

Funding

China Postdoctoral Science Foundation (2011M500948); Guangzhou Huashang College Horizontal Cooperation Research Project (2024HSHX06)

Disclosure statement

The authors declare no conflict of interest.

Author contributions

Lu Zhifang was responsible for topic proposal, interview recording provision, and manuscript review and

revision; Xie Manying was responsible for draft writing and revision; Feng Xiaoxin and Lu Di assisted with data organization.

References

[1] Chen ZW, 1984, From Limb and Digital Replantation to the Development of Microsurgery. China Historical Materials of Science and Technology, (02): 47–50.

[2] Pang SF, Wang HQ, Yang XL, 1997, Review and Prospects of the Chinese Journal of Microsurgery. Chinese Journal of Microsurgery, (03): 24–26.

[3] Zhu JK, 1994, Commemorating the 30th Anniversary of the First Report of Limb (Digit) Replantation in China. Chinese Journal of Microsurgery, (01): 1.

[4] Gu LQ, 2022, Pioneer of Chinese Microsurgery—Professor Zhu Jiakai. Chinese Journal of Microsurgery, 45(04): C4-3–C4-5.

[5] Xu CD, 2024, Interview with Professor Xu Dachuan. Chinese Journal of Microsurgery, 47(01): 113–114.

[6] Zhang C, 2014, Introduction to Professor Yang Huilin of The First Affiliated Hospital of Soochow University. Orthopedic Biomechanics and Clinical Research, (3): 69.

[7] Chen ZW, 1979, Overview of the Development of Microsurgery. Shanxi Medical Journal, (05): 1–3.

[8] Zhu JK, Lu ZF, 2012, Interview Recording, 4.

[9] Chen ZW, 1982, Development of Limb (Digit) Replantation and Microsurgery in China. World Science, (04): 16–17.

[10] Pang SF, Wang HQ, 1998, Vigorously Promoting and Developing Microsurgery Holds Great Promise. New Medical Journal, (29): 621–622.

[11] Zhong SZ, 2000, Review and Prospects of Basic Research in Microsurgery. Chinese Journal of Microsurgery, (01): 7–8.

[12] Zhong SZ, Sun B, Chen YL, 1984, Advances in Applied Anatomy for Microsurgery. Journal of Clinical Applied Anatomy, (02): 3–4. DOI: 10.13418/j.issn.1001-165x.1984.02.001.

[13] Hou CL, 2007, China's Contributions to World Microsurgery Development. Chinese Journal of Microsurgery, 30(04): 246–249.

[14] He GC, 1993, Evolution of Applied Anatomy in China—Commemorating the 10th Anniversary of the Chinese Journal of Clinical Anatomy. Chinese Journal of Clinical Anatomy, (01): 1–3. DOI: 10.13418/j.issn.1001-165x.1993.01.001.

[15] Zhu JK, 1997, Celebrating the 20th Anniversary of the Chinese Journal of Microsurgery. Chinese Journal of Microsurgery, (03): 5.

[16] Peng ML, 2006, Centennial Figures of Jinan University: Kuang Gongdao. Journal of Jinan University (Natural Science & Medicine Edition), (02): 333.

[17] Wang SH, Lu JZ, 1965, Animal Experiments on Rabbit Ear Vascular Anastomosis. Beijing Medicine, (01): 20–22.

[18] Pei GX, 2013, Fifty years of microsurgery in China, Microsurgery Branch of the Chinese Medical Association. Proceedings of the 10th National Microsurgery Academic Conference of the Chinese Medical Association and the 50th Anniversary Celebration of the World's First Successful Limb Replantation. Xijing Orthopedic Hospital, Fourth Military Medical University, 3.

[19] Zhan HC, Wang GY, 2011, Wang Shuhuan: A Great Physician Who Opened a New Chapter in Hand Surgery in

New China. China Medical Science, 1(02): 1–3.

[20] Wang JL, Wang CQ, 2022, A Decade of Microsurgery. Chinese Journal of Orthopedic Surgery, (24): 2209–2212.

[21] Liu XL, Pang SF, Zhu JK, 2003, Advancing with the Times, Striving to Open New Prospects for Microsurgery in China. Chinese Journal of Microsurgery, (01): 1–2.

[22] Zhu JK, Pang SF, 2000, Propelling China's Microsurgery into the New Millennium. Chinese Journal of Microsurgery, (01): 4–6.

[23] Chen ZW, 1998, Current Status and Prospects of Microsurgery. Chinese Journal of Microsurgery, (01): 1–2.

Publisher's note

Bio-Byword Scientific Publishing remains neutral with regard to jurisdictional claims in published maps and institutional affiliations.

Bone and Arthrosurgery Science, 2026, Volume 4, Issue 5
https://www.bbwpublisher.com/journal/BAS
Online ISSN: 2981-8222
Print ISSN: 3083-4856

Effects of Extracorporeal Shock Wave Therapy on Visual Analogue Scale Scores and Serum Osteocalcin in Patients with Old Thoracolumbar Compression Fractures

Zhenyu Wang

Guangzhou Red Cross Hospital of Jinan University, Guangzhou 510000, Guangdong, China

Copyright: © 2026 Author(s). This is an open-access article distributed under the terms of the Creative Commons Attribution License (CC BY 4.0), permitting distribution and reproduction in any medium, provided the original work is cited.

Abstract: *Objective:* To investigate the effects of extracorporeal shock wave therapy (ESWT) on visual analogue scale (VAS) pain scores and serum osteocalcin (bone Gla protein, BGP) levels in patients with old thoracolumbar compression fractures. *Methods:* Ninety patients with old thoracolumbar compression fractures admitted between February 2023 and February 2026 were enrolled and randomized, using a random number table, into an observation group and a control group of 45 patients each. The control group received conventional anti-osteoporotic therapy and rehabilitation, while the observation group additionally underwent focused ESWT. VAS scores, serum BGP levels, and radiographic fracture healing were compared between the two groups before treatment and at 4 and 12 weeks of treatment. *Results:* At 4 and 12 weeks of treatment, all of the above indices were superior in the observation group compared with the control group ($P < 0.05$). *Conclusion:* ESWT can effectively alleviate pain, raise serum osteocalcin levels, and promote the fracture healing process in patients with old thoracolumbar compression fractures.

Keywords: Extracorporeal shock wave therapy; Thoracolumbar spine; Old fracture; Visual analogue scale; Osteocalcin

Online publication: November 20, 2026

1. Introduction

Thoracolumbar compression fracture is the most common type of fragility fracture in the osteoporotic population, with a particularly high incidence among postmenopausal women. Most fresh fractures heal satisfactorily with conservative treatment; however, some patients progress to old (chronic) fractures because of delayed presentation, inadequate immobilization, or a poor state of bone metabolism, manifesting as persistent low back pain, loss of vertebral body height, and arrested fracture healing. Such patients suffer from protracted, refractory pain and a marked decline in quality of life, and their clinical management is highly challenging [1]. Extracorporeal shock wave therapy (ESWT), as a non-invasive physical intervention,

has accumulated relatively robust evidence in the treatment of nonunion and delayed union of fractures [2]; its biological effects involve mechanical stress-induced microdamage stimulation, improvement of local blood supply, and activation of osteogenesis-related signaling pathways [3]. Osteocalcin (bone Gla protein, BGP) is synthesized and secreted by osteoblasts and is a classical serological marker reflecting osteoblastic activity [4]. Nevertheless, for the specific population of patients with old thoracolumbar compression fractures, systematic observation of the dynamic effects of ESWT on pain and osteocalcin levels is still lacking. Using a randomized controlled design, this study therefore investigates the effects of ESWT on VAS scores and serum BGP in patients with old thoracolumbar compression fractures, with a view to providing a reference for clinical decision-making.

2. Materials and methods

2.1. General information

Ninety patients with old thoracolumbar compression fractures who were diagnosed and treated between February 2023 and February 2026 were enrolled as the study sample and were randomized into two groups of 45 patients each. Among the 45 patients in the control group, the male-to-female ratio was 23:22; the age ranged from 35 to 78 years, with a mean of 51.16 ± 7.24 years; and the disease course was 2–10 months, with a mean of 5.44 ± 1.28 months. Among the 45 patients in the observation group, the male-to-female ratio was 24:21; the age ranged from 34 to 79 years, with a mean of 50.12 ± 6.82 years; and the disease course was 1–10 months, with a mean of 5.17 ± 1.65 months. There were no statistically significant differences in baseline characteristics between the two groups ($P > 0.05$), indicating comparability.

2.1.1. Inclusion criteria

(1) Single-segment thoracolumbar (T10–L2) compression fracture confirmed by MRI and radiography, with the degree of vertebral compression between 15% and 40%;
(2) Disease course ≥3 months, with imaging showing a distinct fracture line but no continuous bridging callus, consistent with the diagnosis of an old fracture;
(3) Bone mineral density T-score ≤−2.5 SD;
(4) No physical pro-healing therapy such as shock wave or pulsed electromagnetic field therapy within 4 weeks before enrolment;
(5) Signed informed consent.

2.1.2. Exclusion criteria

(1) Disruption of the posterior vertebral wall or concomitant neurological injury;
(2) Pathological fracture (caused by tumor or infection);
(3) Skin breakdown or infection in the shock wave treatment area;
(4) Severe cardiovascular or cerebrovascular disease, coagulation dysfunction, or cognitive impairment precluding cooperation with assessments;
(5) Previous history of spinal surgery.

2.2. Methods

2.2.1. Control group

Basic anti-osteoporotic therapy was given, comprising calcium carbonate D3 tablets (600 mg/day, orally) combined with alendronate sodium (70 mg/week, orally), together with instruction in isometric contraction exercises of the lumbar and dorsal muscles and progressive weight-bearing activities. The course of treatment was 12 weeks.

2.2.2. Observation group

In addition to the regimen of the control group, focused extracorporeal shock wave therapy was applied. An electromagnetic shock wave device (Dornier AR2, Germany) was used. Before treatment, the fractured vertebral body and the adjacent endplate region were localized under fluoroscopic guidance, and the treatment target area was marked on the body surface. The parameters were set as follows: energy flux density 0.25 mJ/mm^2, frequency 4 Hz, 2,000 shocks per session, and focus depth set at 4–6 cm according to the position of the vertebral body. Treatment was administered once weekly, with four consecutive sessions constituting one course; one course was completed in total. During treatment, the patient was placed in the prone position; the superficial bone of the spinous and transverse processes was avoided, and the paraspinal musculature and the region around the fracture line served as the principal targets. The patient's tolerance was ascertained throughout the procedure, and the energy flux density was appropriately reduced if marked discomfort occurred.

2.3. Outcome measures

2.3.1. Visual analogue scale (VAS) for pain

A 0–10 point scale was used, with 0 indicating no pain and 10 indicating the worst imaginable pain. Assessments were performed before treatment and at 4 and 12 weeks of treatment by the same research nurse, who was blinded to group allocation. At each assessment, after the patient had rested in a seated position for 5 minutes, the current severity of low back pain was marked on the scale.

2.3.2. Serum osteocalcin (BGP)

Before treatment and at 4 and 12 weeks of treatment, 3 mL of fasting cubital venous blood was collected, centrifuged at 3000 r/min for 10 minutes, and the separated serum was stored at −80 °C until analysis. BGP levels were measured by electrochemiluminescence immunoassay (Roche Cobas e601), with an intra-assay coefficient of variation (CV) <5% and an inter-assay CV <8%.

2.3.3. Radiographic callus score

At 12 weeks of treatment, anteroposterior and lateral radiographs of the thoracolumbar spine were obtained, and healing was graded with reference to the Fernández-Esteve callus scoring criteria: 0 points, no callus formation; 1 point, indistinct fracture ends with a small amount of cloud-like callus; 2 points, callus formation but the fracture line still visible; 3 points, callus bridging the fracture line with blurring of the fracture line; 4 points, disappearance of the fracture line with bony union. The images were read independently by two senior radiologists, and disagreements were resolved by consensus.

2.4. Statistical analysis

Data were processed using SPSS 26.0 software. Measurement data and count data were expressed as mean ± standard deviation (SD) and (%) respectively, and comparisons were performed using the *t*-test and the χ^2 test accordingly. Statistical significance of the results was judged primarily by the *P* value, with $P < 0.05$ considered to indicate a statistically significant difference.

3. Results

3.1. Comparison of VAS scores between the two groups

Compared with the control group, the observation group had lower VAS scores ($P < 0.05$), as shown in **Table 1**.

Table 1. Comparison of VAS scores between the two groups at different time points (points, mean ± SD)

Group	*n*	Before treatment	4 weeks of treatment	12 weeks of treatment
Observation group	45	6.24 ± 1.08	3.47 ± 0.92	2.16 ± 0.74
Control group	45	6.18 ± 1.12	4.52 ± 1.03	3.58 ± 0.89
t		0.259	5.100	8.229
P		0.796	0.000	0.000

3.2. Comparison of serum BGP levels between the two groups

Compared with the control group, serum BGP levels were higher in the observation group ($P < 0.05$), as shown in **Table 2**.

Table 2. Comparison of serum BGP levels between the two groups at different time points (ng/mL, mean ± SD)

Group	*n*	Before treatment	4 weeks of treatment	12 weeks of treatment
Observation group	45	14.62 ± 3.27	19.85 ± 3.96	23.47 ± 4.12
Control group	45	14.38 ± 3.14	16.92 ± 3.58	19.04 ± 3.87
t		0.355	3.682	5.257
P		0.723	0.000	0.000

3.3. Comparison of radiographic callus scores between the two groups

The proportion of patients achieving bony union (4 points) was higher in the observation group than in the control group ($P < 0.05$), as shown in **Table 3**.

Table 3. Comparison of radiographic callus scores between the two groups at 12 weeks of treatment [*n* (%)]

Group	*n*	0 points	1 point	2 points	3 points	4 points
Observation group	45	0 (0.00)	5 (11.11)	12 (26.67)	15 (33.33)	13 (28.89)
Control group	45	3 (6.67)	11 (24.44)	16 (35.56)	10 (22.22)	5 (11.11)
χ^2	–	3.103	2.737	0.829	1.385	4.444
P	–	0.078	0.098	0.362	0.239	0.038

4. Discussion

Osteoporotic thoracolumbar compression fracture is a highly prevalent type of fragility fracture in the elderly: vertebral bone mass is reduced, and bone microarchitecture is disrupted, so that vertebral collapse can occur under only minor external force. Most fresh fractures heal gradually after standardized conservative treatment; however, in some patients, factors such as poor early pain control, prolonged bed rest, poor adherence to lumbar and dorsal muscle exercise, and a low baseline level of bone metabolism lead to arrest of the reparative process and evolution into an old compression fracture [5,6]. The cardinal manifestation in these patients is persistent chronic low back pain, which arises not solely from the fractured ends but is frequently compounded by paraspinal muscle spasm, vertebral instability, and local aseptic inflammation. Chronic pain restricts activity and further aggravates bone loss, creating a vicious circle of "pain → reduced activity → worsening osteoporosis → delayed fracture healing" that poses considerable difficulty for clinical treatment [7]. Current conventional regimens combining anti-osteoporotic medication with rehabilitation training can improve bone mass and relieve pain of muscular origin, but they provide limited osteogenic stimulation at the fracture site; in many patients, the fracture line persists for a long time, callus grows slowly, and painful symptoms linger for months or even longer. There is therefore an urgent need for a safe, minimally invasive pro-repair intervention that can be delivered in primary care settings [8].

Extracorporeal shock wave therapy is a non-invasive physical treatment that has been widely used for delayed union and nonunion of fractures, tendinopathies and chronic pain disorders. When shock waves reach the target tissue, they generate mechanical stress, producing controlled microdamage in bone and soft tissue and thereby initiating the reparative cascade [9]; at the same time, they dilate local microvessels, improve microcirculation, upregulate osteogenesis-related growth factors, and recruit mesenchymal stem cells to differentiate into osteoblasts, thereby enhancing local osteogenic activity—this constitutes the core mechanism by which ESWT promotes fracture repair. Osteocalcin is specifically secreted by osteoblasts and is a commonly used clinical marker of osteoblastic activity; an increase in serum BGP indirectly reflects active osteoblast proliferation and accelerated bone formation [10,11]. In the present study, there were no significant differences in VAS scores or serum BGP levels between the two groups before treatment, indicating balanced baselines; at 4 and 12 weeks of treatment, the observation group had lower VAS scores and higher serum BGP levels than the control group ($P < 0.05$). This suggests that adding focused ESWT to conventional anti-osteoporotic and rehabilitation therapy can both rapidly relieve resting low back pain and upregulate serum osteocalcin, activating systemic and local osteogenic metabolism [12].

Pain relief is likely to occur through three pathways. First, shock waves inhibit the release of local inflammatory mediators and reduce the sensitivity of nociceptors, thereby directly alleviating the pain of chronic aseptic inflammation. Secondly, they improve blood supply to the paraspinal soft tissues and release spasm of the lumbar and dorsal muscles, thus reducing referred pain caused by muscular tension. Thirdly, once osteogenic activity has been enhanced and callus has formed at the fracture ends, vertebral stability improves, and the irritating pain provoked by micromotion is consequently attenuated [13]. In this study, treatment was delivered with the patient prone, targeting the paraspinal region and the area around the fracture line while avoiding danger zones such as the spinous processes and the spinal canal, at a moderate energy flux density once weekly for four sessions—an approach that balances efficacy and safety. No adverse events such as nerve irritation, subcutaneous hematoma, or further vertebral collapse occurred, indicating that the protocol is suitable for patients with old osteoporotic vertebral compression fractures, whose tolerance

is relatively poor. In the control group, as anti-osteoporotic therapy and rehabilitation training progressed, VAS scores also fell, and BGP rose slightly, showing that standardized basic treatment can itself improve bone metabolism and muscle-derived pain; however, its onset is slower and its osteogenic stimulation at the fracture site is insufficient, and the difference from the observation group was marked [14].

At 12 weeks of treatment, the proportion of patients with callus bridging and bony union (4 points) was higher in the observation group than in the control group ($P < 0.05$), while the remaining grades showed no statistically significant between-group differences. This indicates that ESWT does not achieve rapid bony union in all patients; rather, its principal advantage lies in increasing the proportion achieving complete bony union. Some patients still achieved only scant callus or blurring of the fracture line, suggesting that repair of old vertebral compression fractures is a lengthy process for which a single shock wave intervention has limitations. In old fractures, the vertebral trabeculae are collapsed, local blood supply is poor and, superimposed on persistent osteoporosis, the osteogenic microenvironment is unfavorable. Shock waves serve mainly to "initiate repair"; anti-osteoporotic medication is still required to continuously improve systemic bone metabolism, together with lumbar and dorsal muscle training to maintain the mechanical stability of the vertebral body, and only the synergy of all three yields a satisfactory outcome. This also demonstrates the rationality of the combined regimen used in this study: shock waves alone cannot correct osteoporosis, osteogenic activity is difficult to sustain, and the fracture remains at risk of impaired healing [15,16].

This study has certain limitations. First, it was a single-center study with a relatively small sample size and a follow-up period of only 12 weeks; only short-term VAS scores, osteocalcin levels, and radiographic callus scores were observed, and longer-term indices (at 6 months and 1 year), such as maintenance of vertebral body height, risk of re-fracture, and disability indices, were not assessed, so the long-term efficacy remains unclear. Secondly, serum BGP was used as the marker of osteogenesis; being a systemic index, it cannot reflect local osteogenic changes at the fractured vertebra with complete specificity, and future studies could combine several bone metabolism markers—such as bone-specific alkaline phosphatase and N-terminal propeptide of type I procollagen—for a more comprehensive assessment. Thirdly, no subgroup comparisons of different shock wave energy levels, numbers of shocks, or treatment courses were performed, so the optimal treatment parameters remain to be explored. Fourthly, radiography has a limited ability to identify fine callus; where conditions permit, thin-slice CT reconstruction could be used to evaluate fracture healing and improve the objectivity of assessment.

5. Conclusion

In summary, focused extracorporeal shock wave therapy combined with conventional anti-osteoporotic and rehabilitation therapy can effectively reduce VAS scores for low back pain, upregulate serum osteocalcin levels, promote callus growth at the fracture ends, and increase the proportion of bony union in patients with old thoracolumbar compression fractures. Being minimally invasive and having a favorable safety profile, it is suitable for use as a conservative treatment for such patients in primary care hospitals, and offers a new therapeutic option for old osteoporotic vertebral compression fractures in patients who are unwilling to undergo vertebroplasty or have no surgical indication. In clinical application, the indications must be strictly observed, pre-operative imaging should be used for precise localization, shock wave energy and targets should be carefully controlled, and long-term anti-osteoporotic treatment and functional exercise should be

maintained, so that the therapeutic effect can be continuously consolidated.

Disclosure statement

The author declares no conflict of interest.

References

[1] Fu SG, Min ZR, Zhou M, et al., 2025, Factors Influencing the Efficacy of Extracorporeal Shock Wave as Adjuvant Therapy for Nonunion After Long Bone Shaft Fracture Surgery. China Modern Medicine, 32(9): 44–47.

[2] Cheng ZX, Fan XC, Feng ZY, et al., 2023, Chinese Expert Consensus on the Clinical Application of Extracorporeal Shock Wave Therapy in Pain Medicine (2023 Edition). Chinese Journal of Painology, 19(2): 220–235.

[3] Cao XT, 2024, Observation on the Effect of Radial Extracorporeal Shock Wave Combined with Ultrasound Therapy in Patients with Skin Scarring After Knee Fracture Surgery. Da Yisheng, 9(18): 37–39.

[4] Xiao ML, Li HQ, Zhao ZH, 2024, Clinical Effect of Early Grip Strength Training Combined with Extracorporeal Shock Wave Therapy for Osteoporotic Distal Radius Fractures: A Retrospective Cohort Study. Journal of Practical Hand Surgery, 38(4): 531–534.

[5] Nie H, Yin L, Liu HW, et al., 2023, Progress in the Clinical Application of Extracorporeal Shock Wave Therapy for Fracture Nonunion. Journal of Changchun University of Chinese Medicine, 39(1): 104–107.

[6] Zhao XD, Lin M, Chen MY, et al., 2023, Efficacy of Extracorporeal Shock Wave Therapy on Fracture Healing and Dynamic Changes in Inflammatory Factors. Guizhou Medical Journal, 47(12): 1881–1883.

[7] Wang SN, Wu WX, Sun Y, et al., 2025, Risk Factors for Delayed Union After Internal Fixation of Upper Limb Long Bone Fractures and Analysis of the Efficacy of Extracorporeal Shock Wave Therapy. Chinese Journal of Bone and Joint Injury, 40(7): 771–774.

[8] Chen ZH, Huang C, Zhao J, et al., 2025, Progress in the Application of Platelet-Rich Plasma Combined with Extracorporeal Shock Wave Therapy for Fracture Nonunion and Delayed Union. Chinese Journal of Bone and Joint Injury, 40(5): 496–499.

[9] Tang HT, Sun RB, Tian TT, et al., 2024, Extracorporeal Shock Wave Therapy Combined with Local Injection of Autologous Bone Marrow Blood Active Concentrate and Platelet-Rich Plasma for Lower Limb Fracture Nonunion. The Journal of Traditional Chinese Orthopedics and Traumatology, 36(6): 61–65, 80.

[10] Li HY, Hao B, Li Y, et al., 2023, Effect of Extracorporeal Shock Wave Therapy Following PFNA for Intertrochanteric Femoral Fractures in the Elderly. Ningxia Medical Journal, 45(8): 714–716.

[11] Zhu YY, Wang KT, 2024, Effect of Extracorporeal Shock Wave Therapy Combined with Autologous PRP Ankle Injection on the Outcome of Arthroscopic Microfracture Surgery for Osteochondral Lesions of the Talus. China Journal of Modern Medicine, 34(17): 1–7.

[12] Xiang JW, Zhang ZX, Chen X, et al., 2025, Clinical Study of Peiyuan Zhuanggu Tablets Combined with Meridian-Based Extracorporeal Shock Wave Therapy for Residual Low Back Pain After PVP for Osteoporotic Lumbar Compression Fractures. New Chinese Medicine, 57(21): 68–71.

[13] Li H, Xiao J, Hu F, et al., 2024, Effect of Shock Wave-Responsive Targeted Controlled Release of Zoledronate Calcium Nanoparticles on Bone Metabolism and Bone Mass in Osteoporosis. Chinese Journal of Medical Frontiers (Electronic Edition), 16(7): 47–54.

[14] Tang HT, Sun RB, Tian TT, et al., 2024, Clinical Efficacy of Shock Wave Combined with Autologous Blood

Active Concentrate in the Treatment of Fracture Nonunion. Journal of Guizhou Medical University, 49(7): 1082–1087.

[15] Guo Y, 2023, Efficacy of Extracorporeal Shock Wave Therapy Combined with Oral Zhuanggu Shujin Decoction for Residual Low Back Pain After PKP for Osteoporotic Vertebral Compression Fractures. Medical Theory and Practice, 36(18): 3217–3219.

[16] Wu J, Zhou LL, Wang Y, 2024, Efficacy of Exercise Therapy Combined with Shock Wave Therapy in Elderly Patients with Osteoporotic Lumbar Vertebral Compression Fractures. Shanghai Medical & Pharmaceutical Journal, 45(20): 36–39.

Publisher's note

Bio-Byword Scientific Publishing remains neutral with regard to jurisdictional claims in published maps and institutional affiliations.

Bone and Arthrosurgery Science, 2026, Volume 4, Issue 5
https://www.bbwpublisher.com/journal/BAS
Online ISSN: 2981-8222
Print ISSN: 3083-4856

Exploratory Comparison of Three Extracorporeal Shock Wave Energy Settings and Two Transosseous Fixation Configurations in a Rabbit Rotator Cuff Repair Model: A Pilot Study

Lin Teng[1], Yue Zhang[1], Dahai Liu[1], Keyuan Ding[1], Gang Zhong[2]*

[1]Department of Orthopaedics, The First People's Hospital of Shuangliu District (West China Airport Hospital of Sichuan University), Chengdu 610200, Sichuan, China
[2]Department of Orthopedic Surgery/Trauma Center, West China Hospital, Sichuan University, Chengdu 610041, Sichuan, China

***Corresponding author:** Gang Zhong, hxzg730927@163.com

Copyright: © 2026 Author(s). This is an open-access article distributed under the terms of the Creative Commons Attribution License (CC BY 4.0), permitting distribution and reproduction in any medium, provided the original work is cited.

Abstract: *Background:* Extracorporeal shock wave therapy (ESWT) has been investigated as an adjunct to tendon-to-bone repair, but its response may vary with energy flux density and fixation configuration. Evidence concerning this possible relationship remains limited. *Methods:* This exploratory pilot study included 33 male New Zealand white rabbits. Three intact contralateral shoulders from animals in the surgery-only category served as intact reference specimens, resulting in 36 shoulder observations across eight analytical categories: intact reference, surgery-only model, and six combinations of single- or double-tunnel repair with ESWT at 0.16, 0.20, or 0.24 mJ/mm^2. Biomechanical and H&E/Masson assessments included one specimen per category. Immunohistochemistry included two specimens in each ESWT category and one specimen in each reference category; three microscopic fields were averaged within each specimen. Findings were summarized descriptively at specimen level. *Results:* Maximum loads recorded for the intact reference, surgery-only model, HS-1, HS-2, MS-1, MS-2, LS-1, and LS-2 specimens were 65, 122, 156, 178, 190, 244, 182, and 112 N, respectively. The MS-2 specimen had the highest observed value, but replication was unavailable, and load displacement curves and failure modes were not recorded. Histological material was illustrative; the LS-1 specimen showed extensive suppurative necrosis/abscess formation. TGF-β staining appeared greater in some medium-energy specimens, whereas CD34 staining varied without an interpretable specimen-level pattern. Total TGF-β and CD34 staining did not establish pathway activation or functional angiogenesis. Separately, animal Z9803 in LS-2 had mild suppuration at the surgical site on postoperative day 16. *Conclusion*: These observations generate hypotheses about possible differences among ESWT energy–fixation combinations but do not identify an optimal dose, demonstrate an energy-by-fixation interaction, or establish biomechanical efficacy, angiogenesis, or a TGF-β-mediated mechanism. A prospectively powered confirmatory study is required.

Keywords: Rotator cuff repair; Extracorporeal shock wave therapy; Tendon-to-bone healing; Pilot study; Exploratory study; Rabbit model

Online publication: November 20, 2026

1. Introduction

Rotator cuff tears are a common cause of shoulder dysfunction, particularly in older adults [1–4]. Although fixation techniques have advanced, durable recovery depends on repair at the tendon-to-bone interface, where fibrocartilage formation and collagen organization are often incomplete [1,2]. Adjunctive strategies intended to influence the local repair environment therefore remain of interest [5,6].

Extracorporeal shock wave therapy (ESWT) is a non-invasive mechanical intervention used across musculoskeletal conditions [7–9]. Experimental work has associated ESWT with changes in angiogenic and matrix-related markers, but effects depend on tissue, timing, and energy exposure [10–13]. Dose-related tissue responses have been described, including adverse changes at higher exposures in rabbit Achilles tendon [14]. Consequently, results from one energy setting cannot be assumed to define an optimum for another tissue or model.

Rotator cuff studies have already reported biomechanical, histological, and vascular observations after ESWT. Feichtinger *et al.* found improved biomechanical findings after shock wave treatment in a chronic rat repair model but did not attribute them to bone microarchitecture [15]. A subsequent rabbit study evaluated a single ESWT setting across several time points and reported changes in tendon integrity, blood perfusion, biomechanics, inflammation, and cell-related outcomes [16]. The remaining exploratory question raised by the current design is whether patterns across graded ESWT settings might differ with transosseous fixation configuration. That question requires adequate independent replication and explicit failure-mode assessment.

Accordingly, we conducted an exploratory pilot study to describe observations across three prespecified ESWT energy flux densities (0.16, 0.20, and 0.24 mJ/mm^2) and two transosseous fixation configurations in a rabbit rotator cuff repair model. The objectives were to document specimen-level biomechanical, histological, and immunohistochemical patterns and generate hypotheses for a subsequent powered study. This study was not designed to establish comparative efficacy, identify an optimal ESWT dose, test an energy-by-fixation interaction, or demonstrate a molecular mechanism.

2. Materials and methods

2.1. Study design, animals, and ethics

This was an exploratory pilot animal study. Thirty-three healthy male New Zealand white rabbits (age, 14 months; weight, 2.3–2.5 kg) were obtained from Chengdu Dashuo Experimental Animal Co., Ltd. (SCXK[Chuan]2022-039). Animals were maintained at 22 ± 2°C on a 12-h light/dark cycle with free access to food and water. The study protocol (project No. 20241226-01) was reviewed and approved by the Institutional Animal Care and Use Committee of Chengdu SenWell Experimental Animal Co., Ltd. (facility license SYXK[Chuan]2020-0232). All procedures were conducted in accordance with applicable national animal-welfare guidance.

The analysis included 33 operated shoulders (**Figure 1**). Three contralateral intact shoulders from animals in the surgery-only category were used as reference specimens, producing 36 shoulder observations but not 36 independent animals. The eight analytical categories were: intact contralateral reference (C; 3 shoulders), double-tunnel surgery-only model (M2; 3 operated shoulders), and six ESWT categories with five operated shoulders each: HS-1, HS-2, MS-1, MS-2, LS-1, and LS-2. The suffix -1 denotes single-tunnel repair and -2 denotes double-tunnel repair; HS, MS, and LS denote 0.24, 0.20, and 0.16 mJ/mm^2, respectively. Endpoint-specific specimen numbers were smaller than the category totals (**Table 1**).

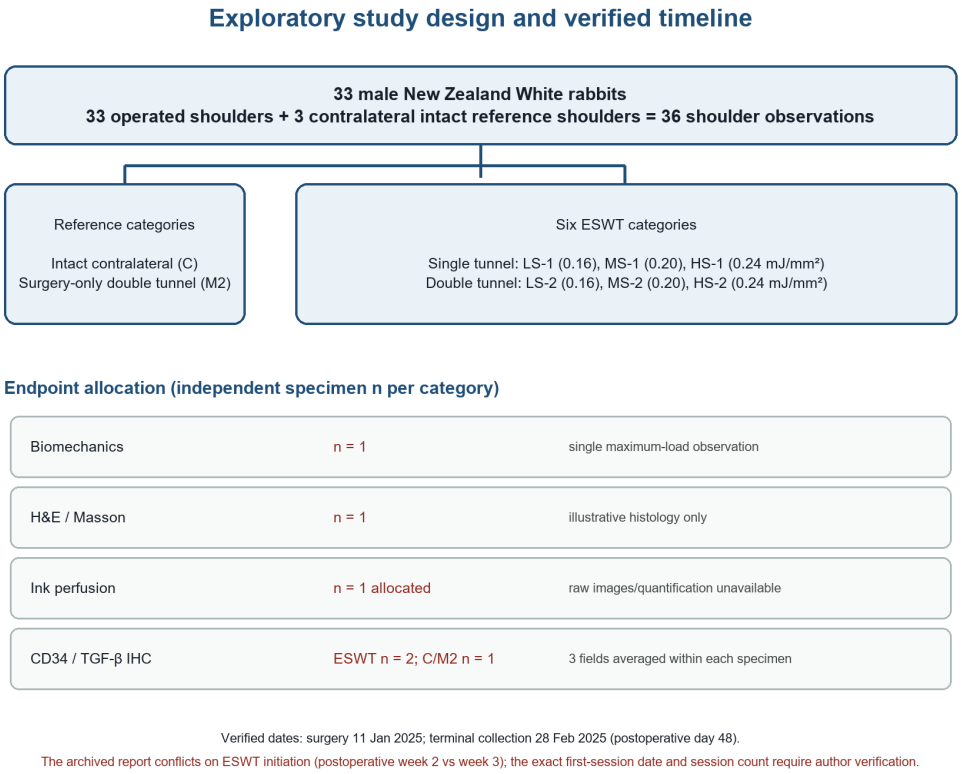

Figure 1. Exploratory study design, endpoint allocation, and available timeline. The study included 33 rabbits and 36 shoulder observations because three intact reference shoulders were contralateral shoulders rather than additional animals. The available records contain conflicting ESWT initiation references (postoperative day 14 and week 3); the exact first-session date and delivered session count could not be verified and are reported as unavailable.

Table 1. Endpoint-specific allocation. *n* denotes independent animal/shoulder specimens, not microscopic fields. Ink-perfusion specimens were allocated, but verifiable raw images and specimen-level quantitative records were unavailable for analysis.

Category	Shoulders in category	Biomechanics (*n*)	H&E/Masson (*n*)	Ink perfusion (*n*)	CD34/TGF-β (*n*)
C (intact contralateral)	3 shoulders	1	1	1 allocated	1 specimen / 3 fields
M2 (double tunnel, no ESWT)	3 shoulders	1	1	1 allocated	1 specimen / 3 fields
HS-1 (0.24, single)	5	1	1	1 allocated	2 specimens / 3 fields each
HS-2 (0.24, double)	5	1	1	1 allocated	2 specimens / 3 fields each
MS-1 (0.20, single)	5	1	1	1 allocated	2 specimens / 3 fields each
MS-2 (0.20, double)	5	1	1	1 allocated	2 specimens / 3 fields each
LS-1 (0.16, single)	5	1	1	1 allocated	2 specimens / 3 fields each
LS-2 (0.16, double)	5	1	1	1 allocated	2 specimens / 3 fields each

2.2. Surgical procedure and postoperative care

General anesthesia was induced with Zoletil. Through a longitudinal incision over the operated shoulder, the supraspinatus tendon was exposed and detached from the greater tuberosity. For repair categories, the tendon was reattached to the footprint with non-absorbable nylon sutures passed through either one oblique bone tunnel or two parallel tunnels created with a 1.0 Kirschner wire. Sutures were placed at 1.5–2-mm intervals

and tied over the tunnels. The surgery-only model used the documented double-tunnel configuration without ESWT. The incision was closed in layers. See **Figure 2**.

Perioperative care included intramuscular penicillin (60,000 U/kg twice daily for 5 days), subcutaneous meloxicam (0.1 mg/kg once daily for 3 days), and daily wound disinfection with povidone–iodine for 7 days. Animals were allowed unrestricted cage activity. Activity, appetite, wound status, behavior, coat condition, and body weight were monitored.

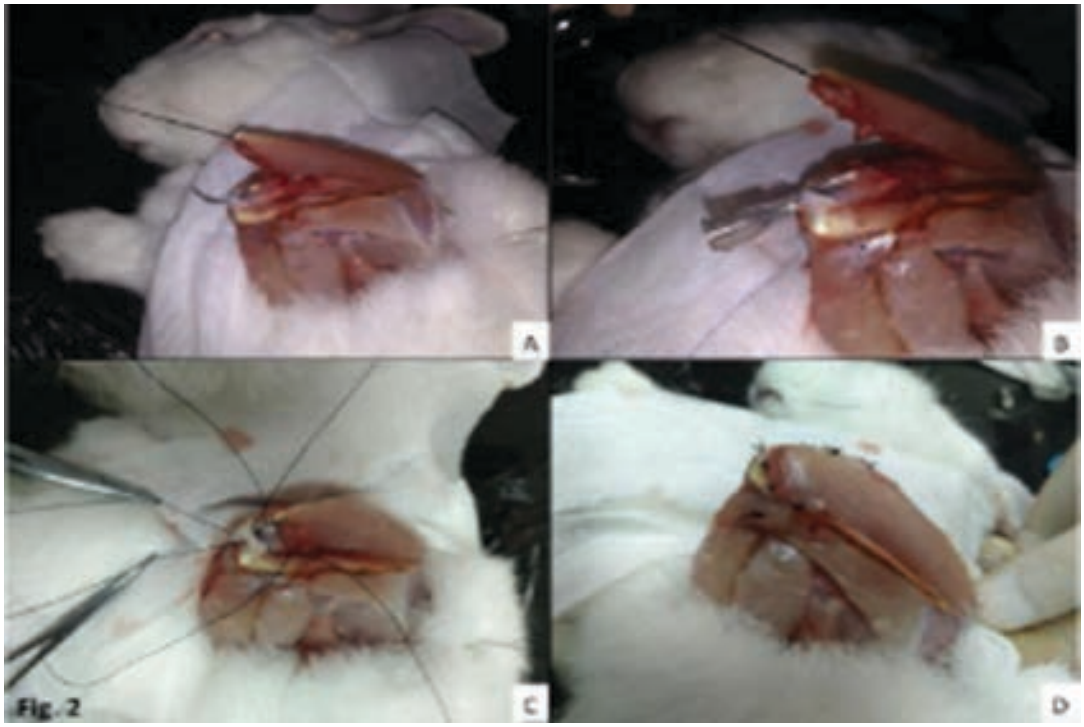

Figure 2. Surgical model and transosseous repair. (A) Supraspinatus detachment. (B) Single-tunnel repair. (C) Double-tunnel repair. (D) Tendon suturing. This figure documents construct preparation; it does not demonstrate biological healing.

2.3. ESWT protocol and study timeline

ESWT was administered with a Kartier 3621EV device to the repair footprint. Prespecified settings were 0.24 mJ/mm^2 (HS), 0.20 mJ/mm^2 (MS), and 0.16 mJ/mm^2 (LS), with 500 impulses at 4 Hz per documented session and nominal administration every 3 days for 30 days. The three settings sampled a limited prespecified range and were not intended to locate a continuous dose optimum.

Surgery was performed on 11 January 2025, and terminal collection was recorded on 28 February 2025 (postoperative day 48). The available records are inconsistent regarding ESWT initiation: one section records grouping after suture removal on postoperative day 14, whereas another states that treatment began 3 weeks after surgery. The individual treatment log was incomplete and did not permit independent verification of the first-session date or delivered session count. These parameters were therefore treated as unavailable, and no definitive treatment schedule was inferred. No claim is made that the chosen timing selectively targeted a defined healing phase.

2.4. Specimen collection and histology

At terminal collection, animals were deeply anesthetized with intramuscular Zoletil (15 mg/kg); after loss of reflexes, euthanasia was completed by intravenous pentobarbital sodium overdose (100 mg/kg) through the marginal ear vein. Supraspinatus–humerus complexes were collected. One specimen per analytical category was fixed in 10% neutral buffered formalin, decalcified, embedded in paraffin, sectioned longitudinally, and stained with hematoxylin and eosin (H&E) and Masson's trichrome.

H&E and Masson material were reviewed descriptively for tissue architecture, inflammatory changes, collagen-containing tissue, and interface continuity. Because only one specimen per category was available and section plane and region of interest were not demonstrably standardized, no group-level score or inference was made. Masson staining was not interpreted as a specific measure of collagen maturity or regenerative enthesis formation.

2.5. Ink perfusion

One specimen per analytical category was allocated to ink perfusion, with vessels to be counted in five high-power fields. However, no verifiable perfusion images or specimen-level quantitative results were available for analysis. This endpoint was therefore classified as unavailable and was not used to support vascular conclusions.

2.6. Biomechanical testing

One humerus–supraspinatus complex per analytical category was mounted in an AGX-S dual-column universal testing machine (Shimadzu, Japan), aligned with the loading axis, and loaded in uniaxial tension until failure. Maximum load (N) was recorded. Load–displacement curves, stiffness values, and failure locations were not recorded. Consequently, construct failure could not be distinguished from failure of the regenerated tendon-to-bone interface.

2.7. Immunohistochemistry

Immunohistochemistry for CD34 and total TGF-β was performed on 14 specimens: two independent specimens in each of the six ESWT categories and one specimen in each reference category. CD34 positivity was observed in endothelial, muscle, adipose, and other spindle-shaped cells; TGF-β positivity was observed in muscle, adipose, and fibrous tissue. For each marker and specimen, three fields acquired at 20× objective and 10× ocular magnification were quantified with Image-Pro Plus 6.0. Integrated optical density (IOD) and tissue area were measured, and IOD/Area was used as mean optical density. The three fields were averaged to obtain a single specimen-level value.

The laboratory reports did not provide verifiable antibody catalog numbers, dilutions, antigen-retrieval conditions, predefined region-of-interest rules, or blinding procedures. These procedural details were unavailable for retrospective verification and are treated as a methodological limitation; they were not inferred from the images.

2.8. Statistical approach

The independent experimental unit was the animal/shoulder specimen. Multiple microscopic fields from the same specimen were technical subsamples and were not treated as independent observations; the three field measurements were averaged to obtain one value per specimen. With one independent specimen per category for biomechanics and H&E/Masson histology, two specimens per ESWT category for immunohistochemistry,

and one immunohistochemical specimen per reference category, within-category variance and confirmatory between-category effects could not be estimated reliably.

Accordingly, all outcomes were presented descriptively using individual specimen values, images, and specimen-level summaries. No between-category hypothesis test, dose-response model, or interaction analysis was used, and no claim of statistical significance or optimality was made. Field-level CD34 comparisons were not retained as inferential results, because fields from the same specimen are not independent observations and therefore do not constitute animal-level evidence. No missing values were imputed.

3. Results

3.1. General observations and local adverse findings

No mortality was recorded before terminal collection. Recovery was not uniformly uneventful. On postoperative day 2, reduced food intake was recorded for Z9107 and Z9505, and an abnormal general condition was recorded for Z9307; on day 9, surgical-site fluid accumulation was recorded for Z9805. On postoperative day 16, Z9803 in LS-2 had mild suppuration at the surgical site. Z9803 later provided the LS-2 biomechanical specimen (112 N). Separately, histopathology of the LS-1 specimen Z9507 showed extensive suppurative necrosis and multiple abscess-like foci with destruction of local muscle and tendon architecture. These events are reported descriptively because the allocation did not permit estimation of complication rates or sensitivity analyses.

3.2. Exploratory biomechanical observations

Biomechanical testing was available for one specimen per analytical category (**Table 2**). Observed maximum loads ranged from 65 N in the intact contralateral specimen to 244 N in the MS-2 specimen. The lowest observed value in this series was therefore recorded in the intact contralateral reference specimen. This is not interpreted as evidence that repaired constructs exceeded native interface strength, because maximum load in a repaired shoulder reflects the combined contribution of the healing interface, the sutures, and the bone tunnels, whereas an intact tendon–bone insertion fails by a different mechanism. Because the two specimen types do not share a comparable failure mode, and given one specimen per category, the intact reference value was not compared with the repaired categories, and no inference regarding relative strength is drawn. The 244 N value was the highest among the eight tested specimens, but it was not a group mean and was not subjected to significance testing. Because load displacement curves and failure locations were unavailable, the observations cannot distinguish regenerated interface strength from suture, tunnel, or construct mechanics.

Table 2. Individual biomechanical observations. Each category contains one tested specimen; values are not group estimates. C and M2 were contralateral shoulders from the same animal (Z9207).

Category	Specimen/animal ID	Observed maximum load (N)
C	Z9207 (contralateral)	65
M2	Z9207 (operated)	122
HS-1	Z9107	156
HS-2	Z9103	178
MS-1	Z9305	190
MS-2	Z9607	244
LS-1	Z9505	182

Category	Specimen/animal ID	Observed maximum load (N)
LS-2	Z9803	112

3.3. Illustrative histological observations

H&E and Masson staining were available from one specimen per analytical category (**Figure 3**). The displayed sections differed in anatomical composition and section plane. Some sampled medium-energy sections contained comparatively aligned collagen-rich tissue, while sampled high-energy sections showed edema and inflammatory changes. The LS-1 specimen showed extensive suppurative necrosis/abscess formation. These appearances are illustrative and cannot establish category-level differences in collagen density, maturity, fibrocartilage regeneration, or tendon-to-bone integration. Masson-positive collagen could include regenerative tissue, fibrotic scar, or both.

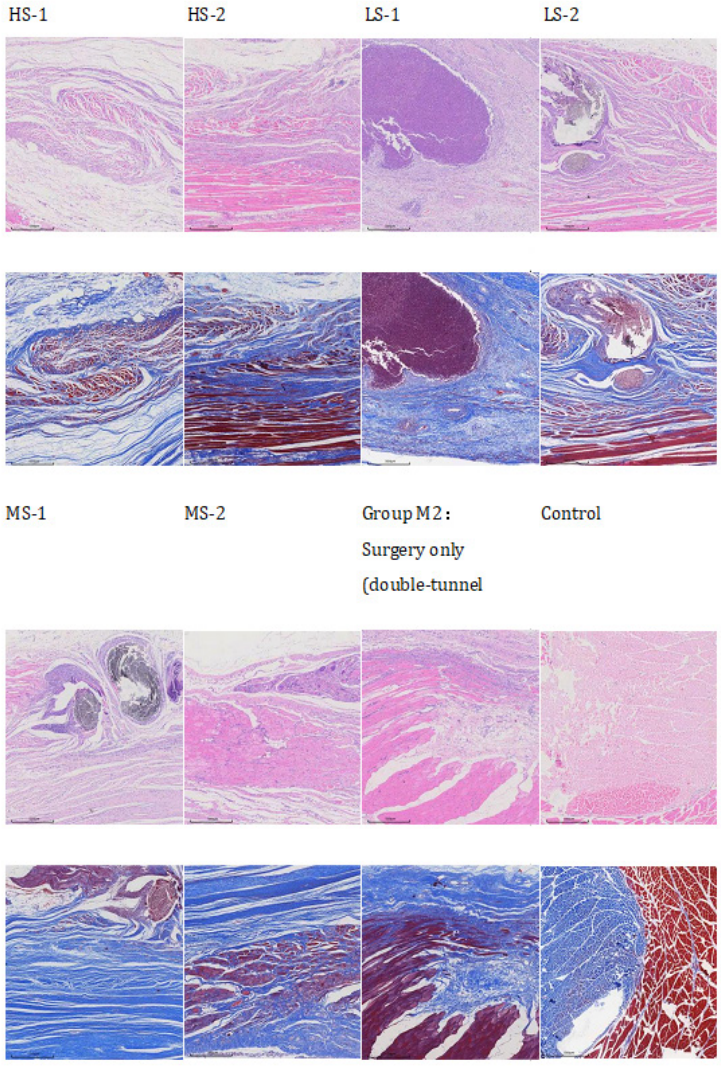

Figure 3. Illustrative H&E and Masson fields from the single available specimen in each analytical category. The first and third rows show H&E; the second and fourth rows show Masson staining. Scale bars = 500 μm. The LS-1 specimen contains an abscess/suppurative lesion. Owing to one specimen per category and non-standardized section composition, the panels do not constitute a group-level comparison of collagen maturity or interface regeneration.

3.4. CD34 immunoreactivity

CD34 immunoreactivity was detected across the sampled specimens (**Figure 4**). Specimen-level IOD/Area values, after averaging three fields within each specimen, were: C 0.0186 (n = 1), M2 0.0294 (n = 1), HS-1 0.0241 and 0.0258, HS-2 0.0301 and 0.0536, MS-1 0.0282 and 0.0349, MS-2 0.0363 and 0.0374, LS-1 0.0378 and 0.0484, and LS-2 0.0266 and 0.0369. The small and unequal numbers of independent specimens did not support a confirmatory category-level comparison. CD34 staining at a single terminal time point did not demonstrate vessel patency, tissue perfusion, or the timing of angiogenesis.

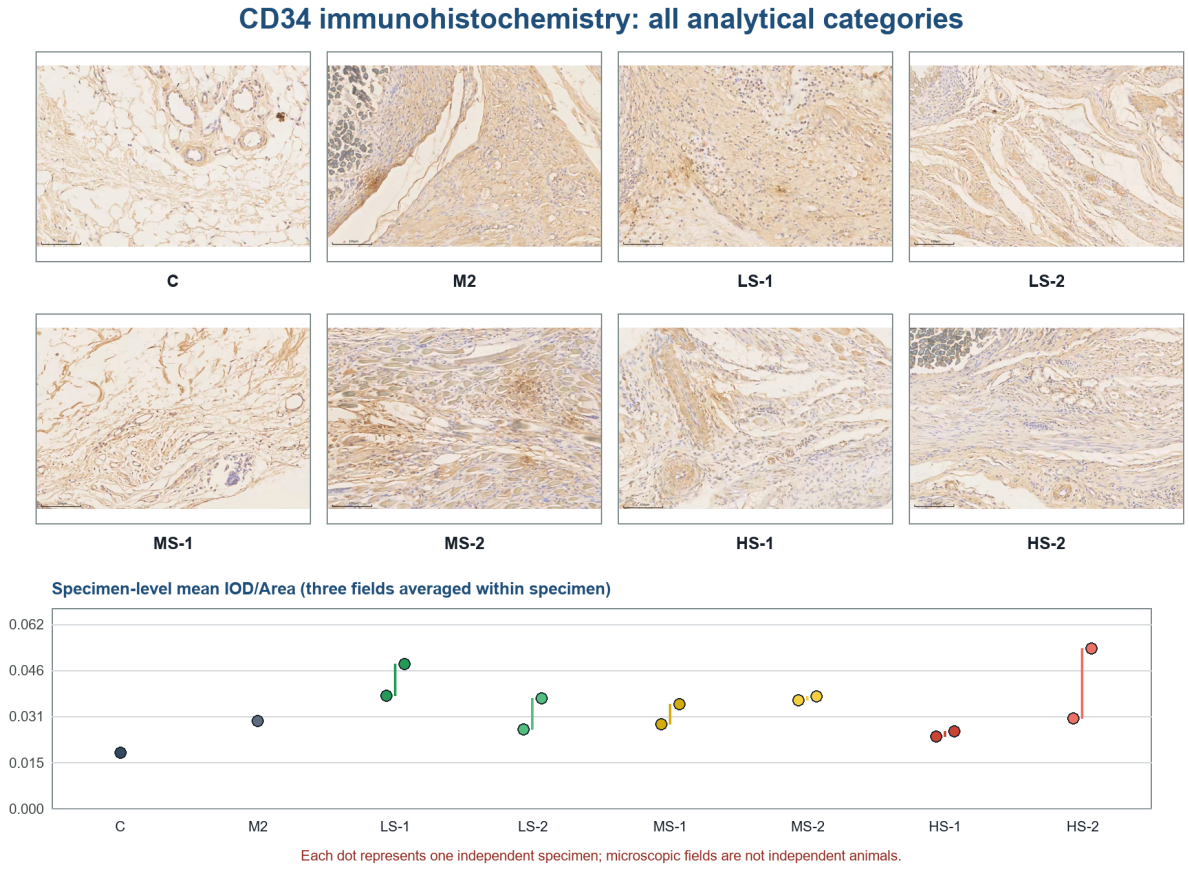

Figure 4. CD34 immunohistochemistry across all eight analytical categories. Images are illustrative fields from the first archived specimen in each category (scale bars embedded in source images = 100 µm). The lower panel shows specimen-level mean IOD/Area after averaging three fields within each specimen. Each dot is one independent specimen; fields are technical subsamples. ESWT categories included two specimens each; C and M2 included one specimen each. No inferential comparison was performed.

3.5. Total TGF-β immunoreactivity

Total TGF-β immunoreactivity varied among specimens (**Figure 5**). Specimen-level IOD/Area values were (**Table 3**): C 0.00945 (n = 1), M2 0.00939 (n = 1), HS-1 0.00538 and 0.00462, HS-2 0.01456 and 0.01064, MS-1 0.05402 and 0.02588, MS-2 0.05199 and 0.02410, LS-1 0.01049 and 0.02079, and LS-2 0.00816 and 0.01922. Some medium-energy specimens had higher observed values than several other specimens, but batch-to-batch variation and sparse independent replication precluded confirmatory inference. Total TGF-β immunoreactivity did not establish active TGF-β/SMAD signaling and did not distinguish regenerative

remodeling from fibrosis or scar formation.

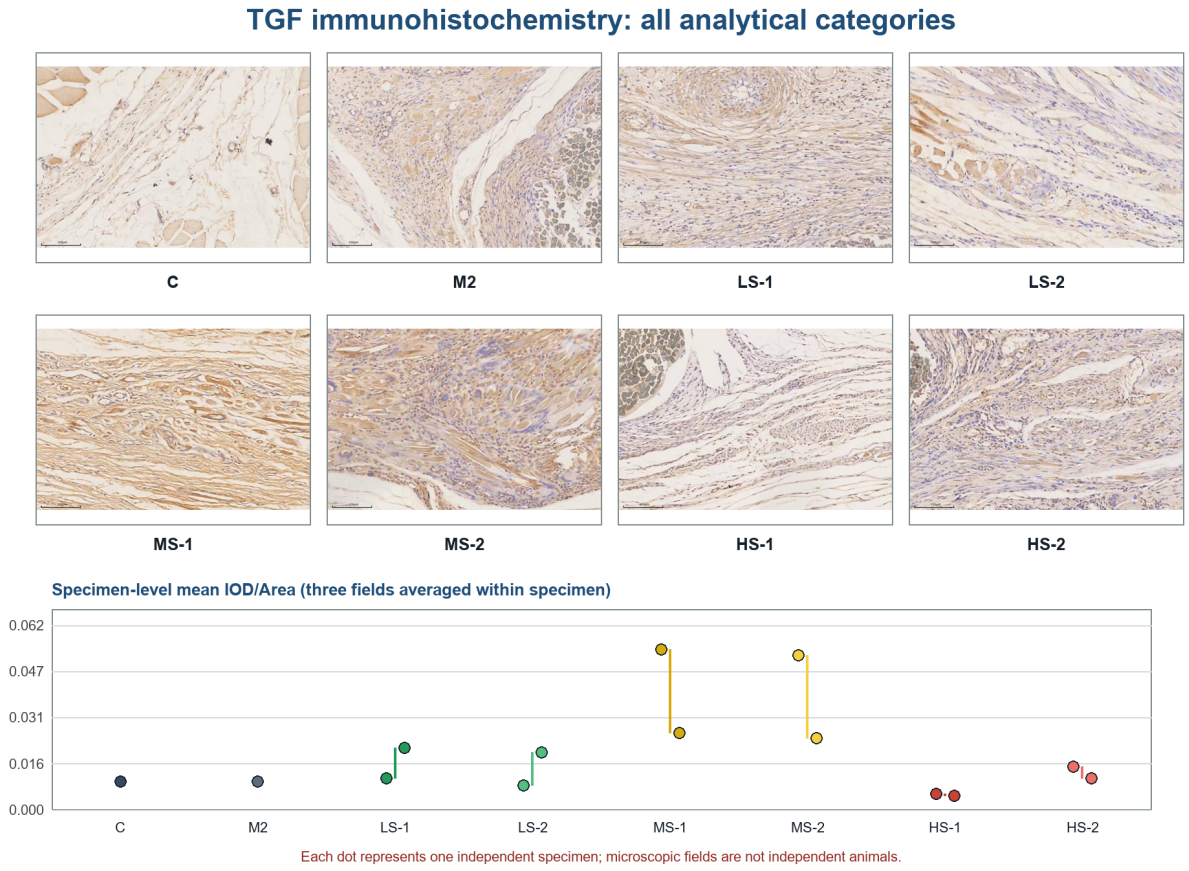

Figure 5. Total TGF-β immunohistochemistry across all eight analytical categories. Images are illustrative fields from the first archived specimen in each category (scale bars embedded in source images = 100 µm). The lower panel shows specimen-level mean IOD/Area after averaging three fields within each specimen. Each dot is one independent specimen; no *P*-values are reported because independent replication was insufficient for confirmatory inference.

Table 3. Specimen-level IOD/Area means for CD34 and total TGF-β after averaging three microscopic fields within each specimen. Specimen 1 and specimen 2 correspond to the two archived batches when available; a dash indicates that only one reference specimen was available. Values are descriptive and are not group estimates.

Category	CD34 specimen 1	CD34 specimen 2	TGF-β specimen 1	TGF-β specimen 2
C	0.018612	—	0.009448	—
M2	0.029384	—	0.009388	—
HS-1	0.024107	0.025821	0.005385	0.004623
HS-2	0.030121	0.053608	0.014555	0.010635
MS-1	0.028232	0.034936	0.054022	0.025877
MS-2	0.036319	0.037428	0.051992	0.024098
LS-1	0.037759	0.048388	0.010493	0.020787
LS-2	0.026581	0.036923	0.008163	0.019220

4. Discussion

This pilot study generated three main specimen-level observations. First, the single MS-2 specimen had the highest maximum load among the eight specimens tested. Second, some medium-energy sections contained comparatively organized collagen-rich tissue in the displayed histology. Third, some medium-energy specimens showed greater total TGF-β staining. These observations raise a hypothesis that ESWT energy and fixation configuration might jointly influence the repair environment. Their apparent agreement, however, is not replicated evidence of efficacy, an optimal energy setting, or an energy-by-fixation interaction.

The biomechanical observations require particular caution. Each category contributed only one specimen. The constructs used non-absorbable sutures, and tunnel number may directly alter load distribution and initial fixation strength. Because load displacement curves, stiffness, and failure sites were not recorded, the 244 N observation in MS-2 cannot be attributed specifically to tendon-to-bone regeneration. It may reflect biological variation, technical variation, construct geometry, or a combination of these factors. The individual values can inform the design of later testing but cannot establish superiority.

The histological material also provides illustrative rather than comparative evidence. With one specimen per category and possible differences in section level and tissue composition, apparent differences in collagen alignment, edema, and inflammatory tissue cannot be generalized. Masson staining identifies collagen-containing tissue but does not establish collagen maturity or distinguish organized enthesis regeneration from fibrotic scar. Future confirmatory work would require standardized harvesting, a prespecified region of interest, blinded scoring, and independent animal replication.

The immunohistochemical findings do not establish a mechanism. Total TGF-β immunoreactivity may accompany matrix remodeling, but it may also occur with fibrosis and myofibroblast activity. Demonstrating a TGF-β-mediated regenerative pathway would require active ligand, downstream signaling such as phosphorylated SMAD2/3, relevant matrix targets, and ideally pathway perturbation. The present pattern is therefore an association for follow-up. Similarly, CD34 staining did not show a stable specimen-level pattern and was measured at only one terminal time point. CD34 immunoreactivity cannot demonstrate that new vessels were patent or perfused. The unavailable ink-perfusion data further prevent functional vascular interpretation.

The local suppurative findings are important. Extensive suppurative necrosis occurred in the examined LS-1 histological specimen, while Z9803 in LS-2 had mild surgical-site suppuration and later contributed to the 112 N load observation. These events indicate that postoperative recovery was not uniformly uneventful and may have influenced local tissue and mechanical outcomes. With the present endpoint allocation, complication incidence and its relationship to energy or fixation cannot be estimated.

Prior animal studies have already examined ESWT in rotator cuff repair using biomechanical, histological, vascular, and molecular outcomes [15,16]. The distinctive hypothesis suggested by this design is whether response to graded ESWT differs according to fixation configuration. This pilot dataset cannot test that interaction. Its contribution is limited to feasibility information, transparent documentation of individual observations, and identification of design requirements for later work. No recommendation about clinical ESWT dose, indication, postoperative timing, or rehabilitation can be derived.

4.1. Limitations

Endpoint-specific independent sample sizes were extremely small: biomechanics and H&E/Masson histology

included one specimen per category; immunohistochemistry included two specimens per ESWT category and one specimen per reference category.

Microscopic fields were technical subsamples within specimens; treating fields as independent animals would be pseudoreplication.

The three intact reference shoulders were contralateral shoulders, so 36 shoulder observations did not represent 36 independent rabbits.

The available records contain conflicting ESWT initiation references (postoperative day 14 vs week 3), and the first-session date and delivered session count could not be independently verified.

Biomechanical curves, stiffness, and failure modes were unavailable, preventing separation of construct mechanics from biological healing.

Histological sampling and regions of interest were not standardized sufficiently for group comparison; Masson staining did not specifically measure collagen maturity.

Ink-perfusion results were unavailable; terminal CD34 staining did not establish functional or early neovascularization.

Total TGF-β staining did not establish signaling activation or causality, and staining-batch effects may have contributed to variation.

Local suppurative events may have influenced outcomes, and the sparse allocation precluded sensitivity analyses.

Only three closely spaced energy settings were sampled; even a replicated difference would not by itself locate a continuous-dose optimum.

5. Conclusion

In this exploratory rabbit study, the highest maximum load was observed in a single specimen treated with 0.20 mJ/mm^2 ESWT and double-tunnel repair, and some medium-energy specimens showed comparatively organized histological features and greater total TGF-β staining. Owing to sparse independent replication and limitations of the available endpoints, these observations do not demonstrate treatment efficacy, an optimal energy, an energy-by-fixation interaction, functional angiogenesis, or a TGF-β-mediated mechanism. The data may assist the design of a future powered study but do not support clinical recommendations.

Acknowledgments

The authors thank the laboratory staff of Sichuan Yanxt Technology Co., Ltd. for technical assistance with histological sectioning and immunohistochemical analysis.

Funding

This study was supported by the Science and Technology Projects of Xizang Autonomous Region, China (Grant No. XZ202501ZY0112), the Medical Research Project of Chengdu Municipal Health Commission (Grant No. 2023131), and the Science and Technology Assistance Program of Sichuan Provincial Department of Science and Technology (Grant No. 2024YFHZ0124).

Disclosure statement

The authors declare no conflict of interest.

References

[1] Bedi A, Bishop J, Keener J, et al., 2024, Rotator Cuff Tears. Nature Reviews Disease Primers, 10(1): 8.

[2] Lapner P, Henry P, Athwal GS, et al., 2022, Treatment of Rotator Cuff Tears: A Systematic Review and Meta-Analysis. Journal of Shoulder and Elbow Surgery, 31(3): e120–e129.

[3] Murrell G, Walton JR, 2001, Diagnosis of Rotator Cuff Tears. The Lancet, 357(9258): 769–770.

[4] Sambandam SN, Khanna V, Gul A, et al., 2015, Rotator Cuff Tears: An Evidence Based Approach. World Journal of Orthopedics, 6(11): 902.

[5] Pasculli RM, Bowers RL, 2022, Evidence-Based Management of Rotator Cuff Tears (Acute and Chronic). Current Physical Medicine and Rehabilitation Reports, 10(3): 239–247.

[6] Trygonis N, Loupasis T, Hautz WE, et al., 2026, Conservative Management of Degenerative Rotator Cuff Tears: A Systematic Review of Long-Term Clinical Outcomes and Cost Effectiveness. Journal of Orthopaedics, 75: 232–241.

[7] De la Corte-Rodríguez H, Román-Belmonte JM, Rodríguez-Damiani BA, et al., 2023, Extracorporeal Shock Wave Therapy for the Treatment of Musculoskeletal Pain: A Narrative Review. Healthcare, 11(21): 2830.

[8] Rhim HC, Shin J, Kang J, et al., 2024, Use of Extracorporeal Shockwave Therapies for Athletes and Physically Active Individuals: A Systematic Review. British Journal of Sports Medicine, 58(3): 154–163.

[9] Zhang X, Ma Y, 2023, Global Trends in Research on Extracorporeal Shock Wave Therapy (ESWT) from 2000 to 2021. BMC Musculoskeletal Disorders, 24(1): 312.

[10] Sugiyama T, Murakami H, Tanaka S, et al., 2025, Effects of Extracorporeal Shockwave Therapy on Wound Healing in Rats. Cureus, 17(5): e83369.

[11] Sung PH, Yeh JN, Yin TC, et al., 2025, Extracorporeal Shockwave Therapy Rescued Mouse Critical Limb Ischemia Via Upregulating GPR120 Against Inflammation and Promoting Angiogenesis for Restoring the Blood Flow in Ischemic Zone-Experimental Study. International Journal of Surgery, 111(3): 2414–2429.

[12] Sung PH, Yin TC, Chai HT, et al., 2022, Extracorporeal Shock Wave Therapy Salvages Critical Limb Ischemia in B6 Mice through Upregulating Cell Proliferation Signaling and Angiogenesis. Biomedicines, 10(1): 117.

[13] Abbas A, Khan Z, Veqar Z, 2023, Dose Dependent Effects of Extracorporeal Shockwave Therapy on Pain and Function in Osteonecrosis of Femoral Head: A Systematic Review. Journal of Clinical Orthopaedics and Trauma, 45: 102275.

[14] Rompe JD, Kirkpatrick CJ, Kullmer K, et al., 1998, Dose-Related Effects of Shock Waves on Rabbit Tendo Achillis. A Sonographic and Histological Study. J Bone Joint Surg Br, 80(3): 546–552.

[15] Feichtinger X, Heimel P, Tangl S, et al., 2022, Improved Biomechanics in Experimental Chronic Rotator Cuff Repair After Shockwaves Is Not Reflected by Bone Microarchitecture. PLoS One, 17: e0262294.

[16] Wang H, Wu F, Miao JQ, 2026, Effects of Extracorporeal Shock Wave Therapy on Tendon Integrity, Biomechanical Strength, Matrix Remodeling, Inflammation, Angiogenesis, and Tenogenic Differentiation in Rotator Cuff Injury. Kaohsiung J Med Sci, 2026: e70260.

Publisher's note

Bio-Byword Scientific Publishing remains neutral with regard to jurisdictional claims in published maps and institutional affiliations.

Bone and Arthrosurgery Science, 2026, Volume 4, Issue 5
https://www.bbwpublisher.com/journal/BAS
Online ISSN: 2981-8222
Print ISSN: 3083-4856

Research Progress on the Correlation between Pseudogout and Periprosthetic Infection after Knee Joint Replacement Surgery

Yijian Jiang[1†], Chengsong Zou[1,2†], Jiahao Lu[1†], Ke Zhou[1], Qili Li[1], Weihao Yu[1], Le Chen[2], Xihua Zhang[1,2]*, Hongchi Yi[1,2]*

[1]Yunnan University of Chinese Medicine, Kunming 650500, Yunnan, China
[2]Ward 3, Orthopedics and Traumatology Center, Yunnan Provincial Hospital of Traditional Chinese Medicine/The First Affiliated Hospital of Yunnan University of Chinese Medicine/The First Clinical Medical College of Yunnan University of Chinese Medicine, Kunming 650021, Yunnan, China
[†]These authors contributed equally to this work and shared first authorship.

Corresponding authors: Hongchi Yi, yyhongchi@126.com; Xihua Zhang, 1546814031@qq.com

Copyright: © 2026 Author(s). This is an open-access article distributed under the terms of the Creative Commons Attribution License (CC BY 4.0), permitting distribution and reproduction in any medium, provided the original work is cited.

Abstract: Knee osteoarthritis (KOA) is one of the most common degenerative joint diseases in the elderly, and knee arthroplasty is an important treatment for end-stage KOA, which can effectively improve knee pain and function. However, postoperative joint swelling and pain are common clinical complications. Pseudogout caused by calcium pyrophosphate deposition and periprosthetic infection are the most confusing causes. The core strategies of the two treatments are completely different, and differential diagnosis is the core difficulty in clinical practice. The purpose of this paper is to systematically review the metabolic background and triggering factors, clinical characteristics, and key points of identification of periprosthetic infection in pseudogout after knee arthroplasty, so as to provide a reference for clinical optimization of the differential diagnosis process and reduction of misdiagnosis.
Keywords: Pseudogout; Knee osteoarthritis; Periprosthetic infection; Knee replacement

Online publication: November 20, 2026

1. Introduction

Knee osteoarthritis (KOA) is a common orthopedic disease in older adults, characterized pathologically by degeneration of articular cartilage and clinically by chronic pain, joint stiffness, and limited mobility, which seriously affects patients' quality of life [1]. With population aging and rising obesity rates [2], the prevalence of KOA has increased year by year, making it one of the leading causes of disability in older adults and imposing a heavy burden on society and families. When KOA progresses to the end stage, conventional conservative treatment is often ineffective, and surgical intervention is usually required [1].

Knee arthroplasty is an effective means of treating end-stage KOA, relieving knee pain, correcting deformity, and restoring joint function [3]. However, postoperative knee swelling and pain are the most common clinical manifestations and are often closely associated with periprosthetic joint infection (PJI). Although the incidence of PJI is relatively low, for affected individuals it can cause the suffering associated with multiple surgeries and long-term antibiotic treatment, seriously affecting functional recovery and long-term implant survival [4]. Therefore, rapid and accurate identification of the nature of postoperative joint swelling and pain is a critical clinical task.

Pseudogout is the acute form of calcium pyrophosphate deposition disease (CPPD); it is caused by the deposition of calcium pyrophosphate (CPP) crystals in the joint and the triggering of an acute inflammatory response, and it occurs predominantly in older adults [5]. The knee is the most commonly involved site in pseudogout, followed by the wrist; the shoulder, hip, and ankle may also be affected [6]. Epidemiological surveys show that prevalence increases with age [7]. The clinical manifestations of pseudogout mainly include sudden severe joint pain, redness, swelling, elevated skin temperature, joint effusion, and systemic inflammatory responses such as fever, which overlap considerably with the manifestations of PJI, making differentiation extremely difficult and posing a major clinical challenge.

Therefore, accurate and timely differentiation between these two conditions is of great clinical significance. However, existing research is relatively limited, and clinicians lack sufficient awareness of this issue. Against this background, from the practical perspective of orthopedic clinical practice, this article systematically reviews the metabolic background and clinical features of pseudogout after joint arthroplasty and the key points for differentiating it from PJI, aiming to provide a reference for clinicians to optimize the differential diagnosis process and reduce misdiagnosis and unnecessary surgical intervention.

2. Current epidemiological status

2.1. Current incidence of postoperative CPPD

The clinical features of CPPD in native joints are relatively well defined. However, when it occurs after joint arthroplasty, its clinical features show certain particularities. Accurate recognition of these features is a prerequisite for timely postoperative diagnosis and avoidance of misdiagnosis. A large number of clinical studies have reported the occurrence of pseudogout after knee arthroplasty, with a very wide range of onset times. Yahia *et al.* [8] reported 7 cases of acute crystal arthritis after joint arthroplasty, with onset from 7 days to 9 years after surgery; 5 cases were confirmed by synovial fluid examination to be caused by calcium pyrophosphate deposition. Matsubara *et al.* [9] reported an individual case with the first episode occurring 14 years after surgery. These cases indicate that the risk window for postoperative pseudogout extends throughout the entire postoperative period rather than being limited to the early postoperative stage.

2.2. Difficulty in differentiating postoperative pseudogout from PJI

The acute attack of CPPD closely resembles PJI, and the two overlap extensively in clinical symptoms, inflammatory markers, and synovial fluid appearance [10]. Clinicians' insufficient understanding of postoperative pseudogout, together with the lack of reliable differential markers, leads to a high misdiagnosis rate. A systematic review by Mashayekhi *et al.* [11] showed that a considerable number of patients received unnecessary surgery and antibiotic treatment because of misdiagnosis. This situation highlights the complexity and urgency of differentiating CPPD from PJI.

3. Risk factors and metabolic background of postoperative pseudogout

In some patients, the acute attack of CPPD is an acute inflammatory response triggered by the formation of calcium pyrophosphate crystals in joint tissues and their release into the joint cavity under external stimulation [12]. In knee arthroplasty, local surgical trauma and systemic metabolic factors superimpose on each other, jointly constituting the pathological basis for crystal deposition and acute attacks.

3.1. Hypercalcemia and calcium pyrophosphate crystal deposition

Hypercalcemia is one of the recognized metabolic risk factors for CPPD [13]. From a microscopic mechanistic perspective, the promotion of crystal deposition by hypercalcemia is not a passive precipitation of calcium salts but an active process involving cell signal transduction. Xie *et al.* [14] suggested that elevated extracellular Ca^{2+} concentration or an imbalance in the Ca^{2+}/Mg^{2+} ratio is a key initiating factor promoting the formation of CPP crystals in cartilage. Specifically, a high-calcium environment can stimulate chondrocytes to release adenosine triphosphate, which activates P2 purinergic receptor signaling pathways, leading to intracellular calcium overload and mitochondrial dysfunction, ultimately promoting the binding of pyrophosphate to calcium ions to form CPP and its deposition in the cartilage matrix. This mechanism provides a key microscopic bridge between hypercalcemia and CPPD, indicating that hypercalcemia can cause CPP deposition through supersaturation of free calcium in the cartilage matrix.

3.2. Multiple upstream pathways leading to postoperative hypercalcemia

Multiple independent upstream factors can indirectly increase the risk of CPPD by elevating serum calcium. In the specific context of joint arthroplasty, these factors may act alone or synergistically.

3.2.1. Hyperparathyroidism

Primary hyperparathyroidism is one of the most common causes of hypercalcemia and is characterized by hypercalcemia and markedly elevated parathyroid hormone (PTH) levels, or inappropriately normal PTH levels [15]. Calcium homeostasis is regulated by calcitonin, vitamin D, and parathyroid hormone [16]; excessive PTH production causes hyperparathyroidism, which in turn leads to hypercalcemia.

3.2.2. Vitamin D excess and *CYP24A1* gene variants

Abnormal vitamin metabolism is another important pathway leading to hypercalcemia and can be divided into endogenous and exogenous situations. Exogenous vitamin D excess is usually caused by long-term inappropriate intake of extremely high doses of vitamin D preparations. Excessive vitamin D supplementation can lead to excessively high serum levels of 25-hydroxyvitamin D, increasing intestinal and renal absorption of calcium and phosphorus and increasing osteoclast activity, thereby causing hypercalcemia [17].

Endogenous vitamin D accumulation mainly arises from loss-of-function mutations in the *CYP24A1* gene. CYP24A1 encodes 24-hydroxylase, which is the key rate-limiting enzyme for the degradation of 1,25-dihydroxyvitamin D [18]. When CYP24A1 has an inactivating mutation, active vitamin D cannot be properly degraded and continuously accumulates; even low-dose or conventional-dose vitamin D supplementation can then cause hypercalcemia. This genetically determined high sensitivity to vitamin D has also been reported in infantile acute hypercalcemia [19]. However, substantial evidence indicates that adults carrying the same mutation can also develop symptoms. Baudart *et al.* [18] reported a 52-year-old patient who presented with CPPD; etiological screening revealed a *CYP24A1* gene mutation, and laboratory tests showed

serum calcium at the upper limit of normal and elevated 1,25-dihydroxyvitamin D. This case report provides a new explanatory dimension for susceptibility to CPPD after knee arthroplasty: patients carrying this gene variant may develop pseudogout after surgery even if preoperative vitamin D supplementation is within the normal range, because of the combined effects of immobilization, stress, and other factors.

3.2.3. Postoperative immobilization and increased bone resorption

In addition to the above endocrine and genetic factors, immobilization after joint arthroplasty itself can be an independent promoting factor for hypercalcemia. Reduced limb activity can enhance osteoclast activity and bone resorption, releasing Ca^{2+} from bone into the blood and consequently elevating serum calcium [20]. For patients with a pre-existing tendency toward hypercalcemia, the superimposed effect of postoperative immobilization may push Ca^{2+} above the threshold for triggering CPPD.

3.3. Comprehensive model of pseudogout after joint arthroplasty

Overall, the occurrence of CPPD after joint arthroplasty is not determined by a single factor but is the result of the combined action of the systemic metabolic background and local surgical trauma. This understanding provides a theoretical framework for comprehending the pathogenesis of postoperative CPPD and also provides a basis for identifying high-risk patients during the perioperative period and formulating preventive strategies.

To facilitate systematic understanding of the core features of CPPD after knee arthroplasty, the key points are summarized in **Table 1**.

Table 1. Core features of pseudogout after knee arthroplasty

Item	Key points	References
Definition	Acute form of CPPD, caused by intra-articular deposition of calcium pyrophosphate crystals that induces acute inflammation.	[5]
Epidemiology	More common in older adults; the knee is frequently involved.	[6,7]
Systemic metabolic factors	Hypercalcemia, hyperparathyroidism, vitamin D excess, *CYP24A1* gene variants.	[13,15–22]
Local triggers	Surgical trauma, postoperative immobilization.	[12,20]
Clinical manifestations	Sudden joint pain, swelling, elevated skin temperature, limited mobility; may be accompanied by fever and systemic inflammatory response.	[8,10,21]
Treatment principles	Acute attack: nonsteroidal anti-inflammatory drugs, colchicine, glucocorticoids.	[31]

Note: The above clinical features are not specific in the postoperative setting and require comprehensive judgment to improve diagnostic accuracy.

4. Differential diagnosis between pseudogout and PJI

Differentiating postoperative CPPD from PJI is the core clinical difficulty. The following discussion addresses three aspects: clinical manifestations, auxiliary examinations, and comprehensive differential diagnosis.

4.1. Common features of clinical manifestations and routine tests

During an acute attack of CPPD, CPP crystals detach from the cartilage surface into the joint cavity and

cause an acute inflammatory response, manifesting as sudden joint redness, swelling, pain, elevated skin temperature, joint effusion, and markedly limited range of motion [12]. Some patients also have fever, but body temperature generally does not exceed 38.5°C; fatigue and other systemic symptoms may also occur [21].

The clinical manifestations of PJI are more varied. Acute PJI also presents mainly with joint redness, swelling, heat, pain, and wound drainage; severe cases may have high fever and chills. Chronic PJI is more insidious, often presenting with persistent joint pain, mild swelling, and progressive decline in joint function; some patients may also develop late manifestations such as implant loosening and sinus tract formation [22,23]. However, it is difficult to make an accurate differentiation between the two based solely on clinical manifestations, and auxiliary examinations are also required.

Routine blood tests and synovial fluid tests also have obvious limitations. A systematic review by Bradley *et al.* [21] found that postoperative inflammatory marker values closely resemble the thresholds for PJI. Al-Jabri *et al.* [4] summarized that C-reactive protein can be significantly elevated both after surgery and in infection; erythrocyte sedimentation rate can continue to rise for up to one year after joint arthroplasty. Although novel synovial fluid markers (such as alpha-defensin and leukocyte esterase) show high sensitivity and specificity in the diagnosis of PJI [24], they cannot diagnose CPPD, and the gross appearance of synovial fluid in both conditions is turbid and inflammatory [25]. For these reasons, relying on a single indicator makes accurate differentiation between the two diseases difficult.

4.2. Differential value of synovial fluid crystal analysis and imaging

Synovial fluid crystal analysis is currently the most direct means of differentiation. The ACR/EULAR classification criteria include the detection of CPP deposition in synovial fluid analysis as one of the core diagnostic bases for CPPD [13]. However, the criteria also note that this method has a certain false-negative rate and inter-observer variability in interpretation. It should be noted that synovial fluid testing should be performed within 12–24 hours after aspiration, and infection and CPP deposition can coexist [26]. Therefore, after joint aspiration, crystal analysis and bacterial culture should be performed simultaneously rather than used as substitutes for each other.

Imaging has auxiliary value in differential diagnosis. Radiography can show chondrocalcinosis [27]. PJI on radiographs mostly shows nonspecific changes such as periprosthetic osteolysis and osteopenia; in late stages, periosteal reaction or implant loosening may be seen, which can serve as an important means of differential diagnosis [28]. Conventional CT can more clearly display fine calcifications not obvious on radiographs, and spectral CT reconstruction can better reflect the contrast between the affected joint and the normal joint [29]. Musculoskeletal ultrasound has high sensitivity for cartilage calcification and meniscal calcification [30]. MRI is mainly used to evaluate the extent of soft tissue involvement in PJI and can clearly show inflammation, abscess, and sinus tracts in the soft tissues around the joint [28]. Therefore, when suspicious signals appear, radiography, CT, musculoskeletal ultrasound, and other auxiliary examinations can be combined for differentiation.

4.3. Optimization strategy for the differential diagnosis process

Given that the above examination methods each have blind spots and that a single indicator cannot reliably distinguish the two diseases, clinical differentiation should follow a hierarchical and stepwise strategy. After joint aspiration, crystal analysis and bacterial culture should be performed simultaneously, and different

pathways should be assigned according to the results, as summarized in **Figure 1**.

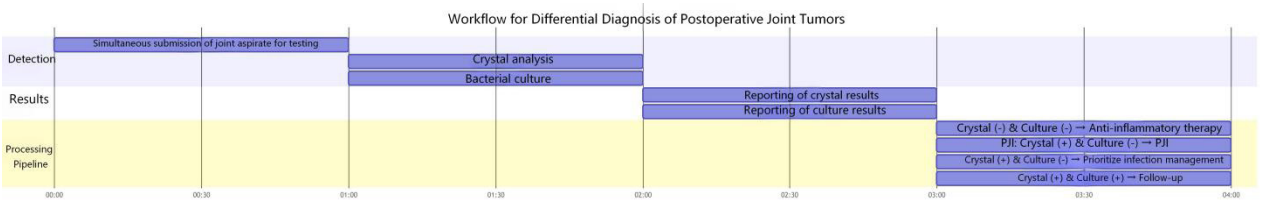

Figure 1. Flowchart for the differential diagnosis of postoperative joint swelling and pain.

To facilitate understanding of the differentiation between postoperative pseudogout and PJI, the key points are summarized in **Table 2**.

Table 2. Differentiation between pseudogout and periprosthetic joint infection

Differential dimension	Pseudogout	Periprosthetic joint infection	References
Systemic symptoms	May have fever, often low-grade	May have high fever and chills	[21]/[22,23]
Local manifestations	Joint redness, swelling, heat, pain, limited mobility	Joint redness, swelling, heat, pain, limited mobility, or accompanied by sinus tract formation and implant loosening	[10,21]/ [22,23,33]
Inflammatory markers	May be markedly elevated in the acute phase, but no characteristic threshold	May be markedly elevated; dynamic monitoring is more valuable	[4,21]
Synovial fluid examination	CPP crystals visible	No crystals	[13]
Bacterial culture	Negative	Positive	[26]
Imaging	Chondrocalcinosis visible on radiography, CT, musculoskeletal ultrasound, etc.	MRI can show the extent of soft tissue involvement	[27–30]/[28]
Treatment principles	Conservative treatment	Surgical intervention	[31]/[32,33]

5. Management strategies and significance

5.1. Fundamental differences in treatment pathways

The management strategies for postoperative CPPD and PJI are completely different, which is precisely why correct differential diagnosis is important.

Acute attacks of CPPD can be controlled with medications, mainly nonsteroidal anti-inflammatory drugs, colchicine, and glucocorticoids [31]. Most patients can achieve relatively rapid symptom relief with oral medications. In contrast, the treatment principle for PJI is primarily surgical. The 2024 guidelines of the British Orthopaedic Association propose a tiered management strategy for PJI [32]: milder cases may undergo debridement combined with antibiotic treatment and implant retention; for cases in which infection is difficult to control, revision surgery is required. The two diseases are diametrically opposed in treatment direction, drug selection, and surgical decision-making. Misdiagnosis not only leads to unnecessary treatment but may also delay the optimal timing of intervention.

5.2. Clinical significance of accurate differential diagnosis

Accurately distinguishing postoperative CPPD from PJI is important in multiple respects, mainly reflected in

the following three points.

The impact on patient prognosis is the most direct. CPPD is an inflammatory disease that can be controlled with medication; timely diagnosis and short-term drug treatment can control symptoms, and joint function is generally not affected [31]. Once misdiagnosed, however, it means long-term antibiotic treatment, unnecessary surgical trauma, and the suffering associated with postoperative rehabilitation. If PJI is not correctly diagnosed early, bacterial biofilms may firmly adhere to the implant surface within weeks, forming a protective barrier against antibiotics and ultimately causing implant–bone interface destruction, bone defects, and implant loosening [22].

Accurate differentiation also has an important impact on the rational allocation of healthcare resources. The cost of revision surgery is usually 2–3 times that of primary arthroplasty. In addition, prolonged hospitalization, repeated imaging examinations, multidisciplinary consultations, and long-term antibiotic treatment bring direct and indirect medical expenditures, and the economic burden caused by misdiagnosis is substantial [33].

In addition, accurate differentiation can reduce patients' psychological burden. As mentioned above, once misdiagnosed as PJI, the uncertainty during long-term treatment and rehabilitation can cause obvious anxiety, which in turn affects rehabilitation training and quality of life [34]. After a clear diagnosis, patients can engage more actively in rehabilitation training. This point is often overlooked in clinical practice, but its impact on final prognosis should not be underestimated.

6. Conclusion and prospects

Postoperative CPPD and PJI show highly similar manifestations after knee arthroplasty, but their treatments are diametrically opposite; accurate differentiation is key to affecting patient prognosis. The two conditions converge through the common endpoint of crystal inflammation and bacterial infection—acute arthritis—but there are fundamental differences in the source of onset, disease course, and management strategies. In brief, CPPD is a crystal-induced aseptic inflammation managed mainly with medication, whereas PJI is an infectious disease caused by bacterial invasion and managed primarily with surgical intervention. Current understanding of this intersecting field is still in its infancy; existing evidence is mostly based on case reports, and systematic differential diagnosis workflows and targeted perioperative management plans are lacking. Future research should focus on the clinical features of the two conditions, explore rapid tools for differentiating infection from crystal detection, and conduct prospective studies in high-risk populations, so as to provide a basis for establishing diagnostic and treatment standards suited to domestic practice.

Funding

Yunnan Provincial Joint Special Project for Basic Research in Traditional Chinese Medicine (Project No.: 202501AZ070001-080)

Disclosure statement

The authors declare no conflict of interest.

References

[1] Liu A, Ma X, Cui Z, et al., 2021, Unicompartmental Versus Total Knee Arthroplasty for Knee Osteoarthritis: A Meta-Analysis. Orthopedic Journal of China, 29(21): 1955–1960.

[2] Huang M, Chen J, Chen S, et al., 2022, Research Progress on Exercise Therapy for Knee Osteoarthritis. Chinese Journal of Sports Medicine, 41(4): 320–329.

[3] Zhao X, Zhang Y, Li Y, 2021, Research Progress on Stepwise Treatment of Knee Osteoarthritis. Modern Journal of Integrated Traditional Chinese and Western Medicine, 30(30): 3410–3415.

[4] Al-Jabri T, Ridha M, Wood MJ, et al., 2024, An Overview of the Current Diagnostic Approach to Periprosthetic Joint Infections. Orthop Rev (Pavia), 16: 120308.

[5] Rosenthal AK, Ryan LM, 2016, Calcium Pyrophosphate Deposition Disease. N Engl J Med, 374(26): 2575–2584.

[6] Wei M, Zhang H, Sun Y, et al., 2022, Application Value of Musculoskeletal Ultrasound in the Differential Diagnosis of Calcium Pyrophosphate Deposition Disease and Gouty Arthritis. Journal of Clinical Ultrasound in Medicine, 24(12): 885–889.

[7] Sirotti S, Scanu A, Pascart T, et al., 2024, Calcium Pyrophosphate Crystal Formation and Deposition: Where Do We Stand and What Does the Future Hold? Curr Rheumatol Rep, 26(10): 354–365.

[8] Yahia SA, Zeller V, Desplaces N, et al., 2016, Crystal-Induced Arthritis After Arthroplasty: 7 Cases. Joint Bone Spine, 83(5): 559–562.

[9] Matsubara H, Kobata H, Kenzaka T, 2026, Acute Calcium Pyrophosphate Crystal Arthritis Occurring Many Years After Total Knee Arthroplasty: A Case Report. Cureus, 18(2): e104367.

[10] George MP, Ernste FC, Tande A, et al., 2019, Clinical Presentation, Management, and Prognosis of Pseudogout in Joint Arthroplasty: A Retrospective Cohort Study. J Bone Jt Infect, 4(1): 20–26.

[11] Mashayekhi Y, Asgari AM, Pahlevan-Fallahy MT, et al., 2025, The Association Between Crystallopathy and Postoperative Complications Following Total Hip and Knee Arthroplasty: A Systematic Review and Meta-Analysis. Ann Med Surg (Lond), 88(2): 1754–1764.

[12] Ivory D, Velázquez CR, 2012, The Forgotten Crystal Arthritis: Calcium Pyrophosphate Deposition. Mo Med, 109(1): 64–68.

[13] Abhishek A, Tedeschi SK, Pascart T, et al., 2023, The 2023 ACR/EULAR Classification Criteria for Calcium Pyrophosphate Deposition Disease. Arthritis Rheumatol, 75(10): 1703–713.

[14] Xie C, Yang C, 2018, Research Progress on the Correlation Between Cartilage Calcium Pyrophosphate Deposition and Ca^{2+}/Mg^{2+} Imbalance. Chinese Journal of Sports Medicine, 37(10): 891–894.

[15] Silva BC, Cusano NE, Bilezikian JP, 2024, Primary Hyperparathyroidism. Best Pract Res Clin Endocrinol Metab, 38(1): 101247.

[16] Tonon CR, Silva TAAL, Pereira FWL, et al., 2022, A Review of Current Clinical Concepts in the Pathophysiology, Etiology, Diagnosis, and Management of Hypercalcemia. Med Sci Monit, 28: e935821.

[17] Chinese Society of Osteoporosis and Bone Mineral Research, Chinese Medical Association, 2025, Consensus on the Clinical Application of Vitamin D and Its Analogues (2025 Version). Chinese Journal of Osteoporosis and Bone Mineral Research, 18(5): 497–517.

[18] Baudart P, Molin A, Cesini J, et al., 2017, Calcium Pyrophosphate Deposition Disease Revealing a Hypersensitivity to Vitamin D. Joint Bone Spine, 84(3): 349–351.

[19] Zhang T, Ma M, Jiang M, 2025, Research Progress in the Treatment of Infantile Hypercalcemia Type 1 Caused by CYP24A1 Variants. Journal of Clinical Pediatrics, 43(11): 872–877.

[20] Gandhi A, Mortensen M, Sunny S, et al., 2021, Immobilization-Induced Hypercalcemia in a Patient with Renal Failure. Endocrinol Diabetes Metab Case Rep, 2021: 21–0086.

[21] Bradley AT, King CA, Lin Y, et al., 2022, Distinguishing Periprosthetic Crystalline Arthropathy from Infection in Total Knee Arthroplasty: A Systematic Review. J Knee Surg, 35(6): 668–675.

[22] Mian HM, Lyons JG, Perrin J, et al., 2022, A Review of Current Practices in Periprosthetic Joint Infection Debridement and Revision Arthroplasty. Arthroplasty, 4(1): 31.

[23] Yilmaz MK, Abbaszadeh A, Tarabichi S, et al., 2023, Diagnosis of Periprosthetic Joint Infection: The Utility of Biomarkers in 2023. Antibiotics (Basel), 12(6): 1054.

[24] Altsitzioglou P, Avgerinos K, Karampikas V, et al., 2024, Point of Care Testing for the Diagnosis of Periprosthetic Joint Infections: A Review. SICOT J, 10: 24.

[25] Cole M, Patel A, Collins L, et al., 2023, Pseudogout After Total Knee Arthroplasty Meeting Minor Criteria for Infection Treated by Polyethylene Exchange. Orthop Rev (Pavia), 15: 67912.

[26] Iwasaki K, Nakamura T, Shin S, et al., 2019, Calcium Pyrophosphate Deposition Disease After Total Knee Arthroplasty: Comparison with Periprosthetic Joint Infection. J Orthop, 16(2): 128–132.

[27] Falkowski AL, Jacobson JA, Kalia V, et al., 2020, Cartilage Icing and Chondrocalcinosis on Knee Radiographs in the Differentiation Between Gout and Calcium Pyrophosphate Deposition. PLoS One, 15(4): e0231508.

[28] Wu X, Tang B, Zhou G, et al., 2023, MRI Manifestations and Diagnostic Value of Infection After Artificial Joint Replacement. Chinese Journal of Gerontology, 43(12): 2896–2899.

[29] Xu W, Xu J, Wang Y, et al., 2025, Clinical Significance of Spectral CT Post-Processing Technology in Differentiating Gouty Arthritis and Calcium Pyrophosphate Deposition Disease. Chinese Journal of Bone and Joint, 14(8): 729–733.

[30] Zheng T, Huang J, Kang C, et al., 2024, Efficacy of Musculoskeletal Ultrasound in the Differential Diagnosis of Gouty Arthritis and Calcium Pyrophosphate Deposition Disease. Heilongjiang Medicine, 37(6): 1427–1430.

[31] Huffman N, Pasqualini I, Surace P, et al., 2023, Diagnosis, Treatment, and Outcomes of Crystalline Arthropathy in the Setting of Total Knee Arthroplasty: A Critical Analysis Review. JBJS Rev, 11(12): e23.00163.

[32] Doski S, Sebastiao A, Thayaparan P, 2024, The Investigation and Management of Peri-Prosthetic Joint Infection After Total Knee Arthroplasty: An Update Based on the Latest British Orthopaedic Association Standard and Speciality Standard Guidelines. Cureus, 16(11): e73315.

[33] Alt V, Szymski D, Rupp M, et al., 2025, The Health-Economic Burden of Hip and Knee Periprosthetic Joint Infections in Europe: A Comprehensive Analysis Following Primary Arthroplasty. Bone Jt Open, 6(3): 298–311.

[34] Parvataneni HK, Gray CF, Prieto HA, et al., 2026, Clinical and Psychosocial Impact of Limited Mobility During the Interstage Period of Two-Stage Revision Arthroplasty for Prosthetic Joint Infection: A State-of-the-Art Review. J Orthop Surg Res, 21(1): 577.

Publisher's note

Bio-Byword Scientific Publishing remains neutral with regard to jurisdictional claims in published maps and institutional affiliations.

Integrated Services Platform of International Scientific Cooperation

Innoscience Research (Malaysia), which is global market oriented, was founded in 2016.Innoscience Research focuses on services based on scientific research. By cooperating with universities and scientific institutes all over the world, it performs medical researches to benefit human beings and promotes the interdisciplinary and international exchanges among researchers.

Innoscience Research covers biology, chemistry, physics and many other disciplines. It mainly focuses on the improvement of human health. It aims to promote the cooperation, exploration and exchange among researchers from different countries. By establishing platforms, Innoscience integrates the demands from different fields to realize the combination of clinical research and basic research and to accelerate and deepen the international scientific cooperation.

Cooperation Mode



Clinical Workers



In-service Doctors





Foreign Researchers

China Collaborators



Oversea Collaborators



Hospital



University



Scientific institutions

Our Journals



The *Journal of Architectural Research and Development* is an international peer-reviewed and open access journal which is devoted to establish a bridge between theory and practice in the fields of architectural and design research, urban planning and built environment research.

Topics covered but not limited to:

- Architectural design
- Architectural technology, including new technologies and energy saving technologies
- Architectural practice
- Urban planning
- Impacts of architecture on environment



Journal of Clinical and Nursing Research (JCNR) is an international, peer reviewed and open access journal that seeks to promote the development and exchange of knowledge which is directly relevant to all clinical and nursing research and practice. Articles which explore the meaning, prevention, treatment, outcome and impact of a high standard clinical and nursing practice and discipline are encouraged to be submitted as original article, review, case report, short communication and letters.

Topics covered by not limited to:

- Development of clinical and nursing research, evaluation, evidence-based practice and scientific enquiry
- Patients and family experiences of health care
- Clinical and nursing research to enhance patient safety and reduce harm to patients
- Ethics
- Clinical and Nursing history
- Medicine



Journal of Electronic Research and Application is an international, peer-reviewed and open access journal which publishes original articles, reviews, short communications, case studies and letters in the field of electronic research and application.

Topics covered but not limited to:

- Automation
- Circuit Analysis and Application
- Electric and Electronic Measurement Systems
- Electrical Engineering
- Electronic Materials
- Electronics and Communications Engineering
- Power Systems and Power Electronics
- Signal Processing
- Telecommunications Engineering
- Wireless and Mobile Communication